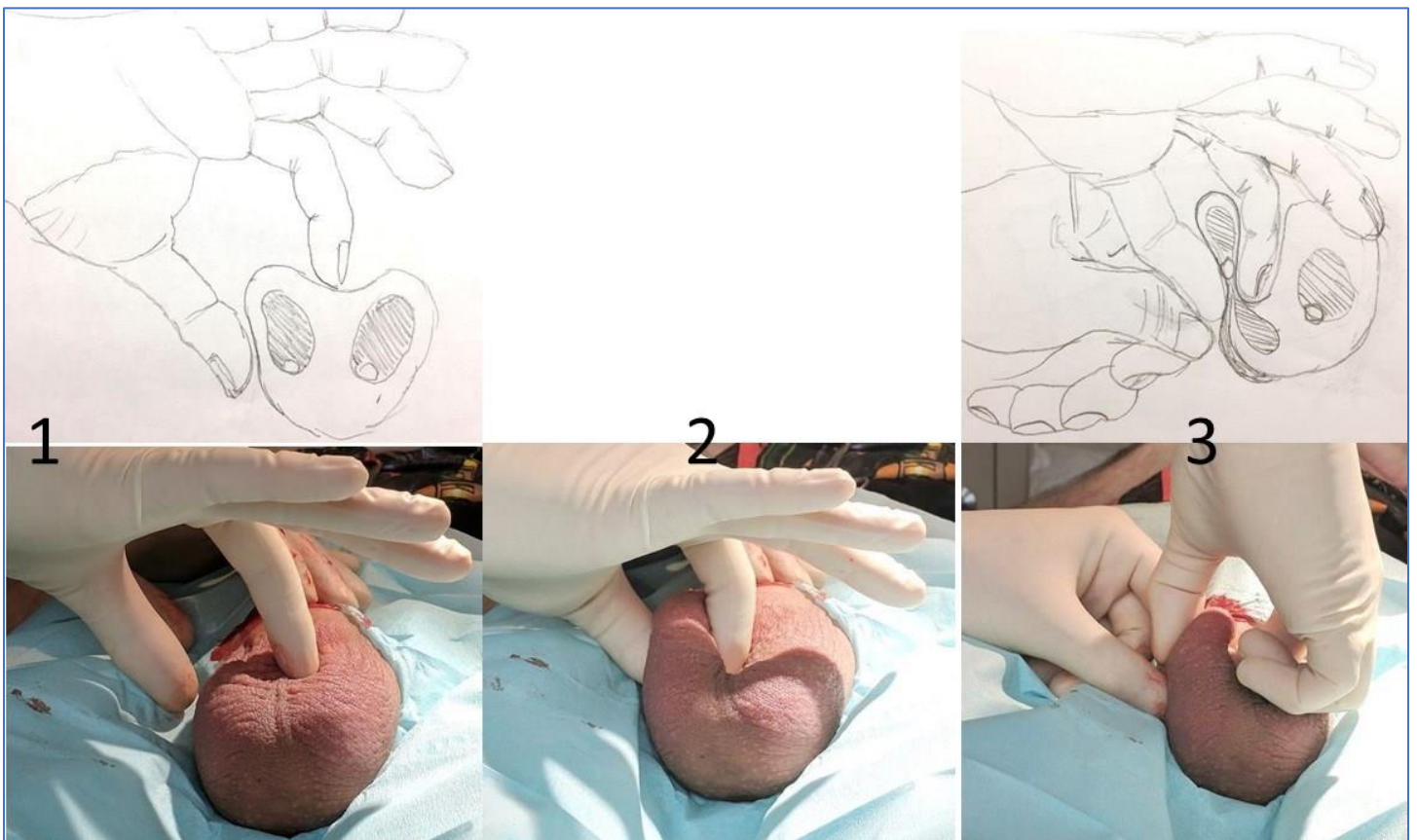


**One Technique to Secure the Ipsilateral Vas with the NSV Ring Clamp in a Patient with a Thick Scrotum and Spermatic Cord:  
Right-Handed Operator**  
Doug Stein, MD

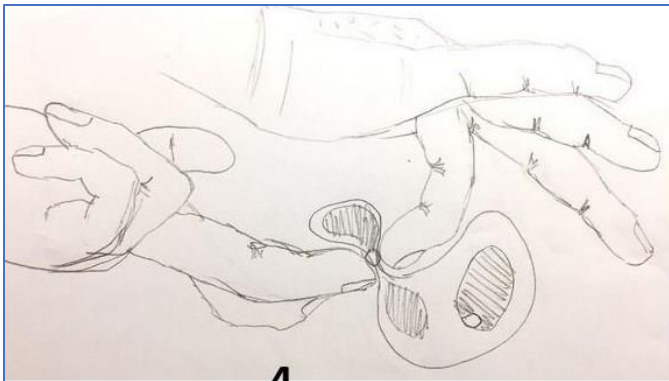
Here are some tips that have made isolation of the ipsilateral vas of the man with a tight scrotum and cord do-able (I won't say "easier") for me.

1. GO SLOWLY, every step of the way. For me, every case is easier if I pretend that the patient is taking a nap and I'm trying to do his vasectomy without waking him up.
2. Shave the scrotum well, even the hair on the lateral scrotal walls. I can't feel as well through hair. Then gather all of the loose hair with 2-inch adhesive tape.
3. Hold the penis out of the way with an elastic band lasso, but not so much that you pull scrotal skin up onto the penile base. You need all the loose skin that you can get. But you don't want a loose short penis getting in the way. Not to mention the fact that the distal urethra is colonized and a potential source of contamination.
4. Prep well ... you may be working there for a while. Warm solution may help to keep the scrotum loose.
5. Wear gloves that are tight – so there are no wrinkles near your fingertips.

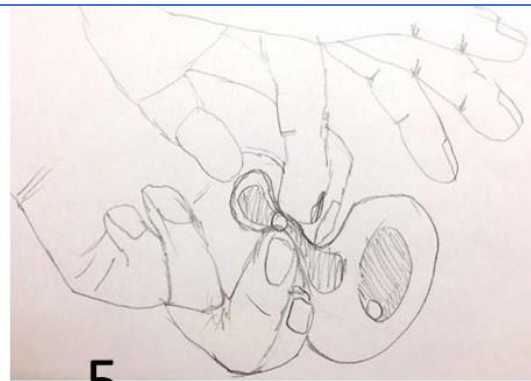
I sketched some drawings and took some photos which show a hand position that has worked well for me on the difficult cases. I'm left handed, but all the sketches and photos have been flipped horizontally make me look like a righty.



Completely encircle the right cord with your right index finger. You can curl the index finger like a hook to coax the vas forward. The other cord structures (hatched in the diagram) will slip through the space between your thumb and index finger but the vas will get wedged there and come forward. Then use the fingers of your left hand to push the thick skin of the para-scrotal fat pad posteriorly so the vas is beneath the thinner scrotal skin.

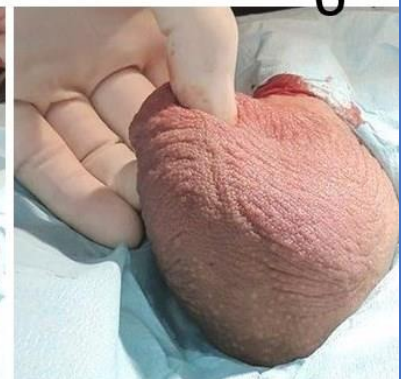
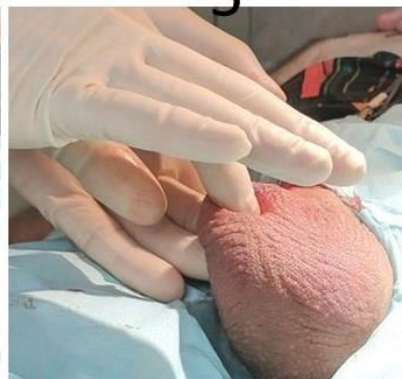
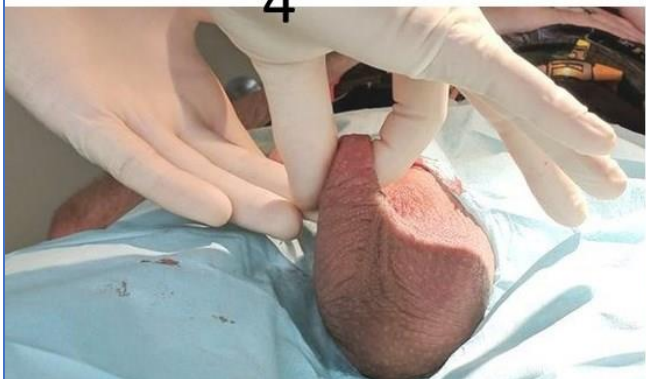4



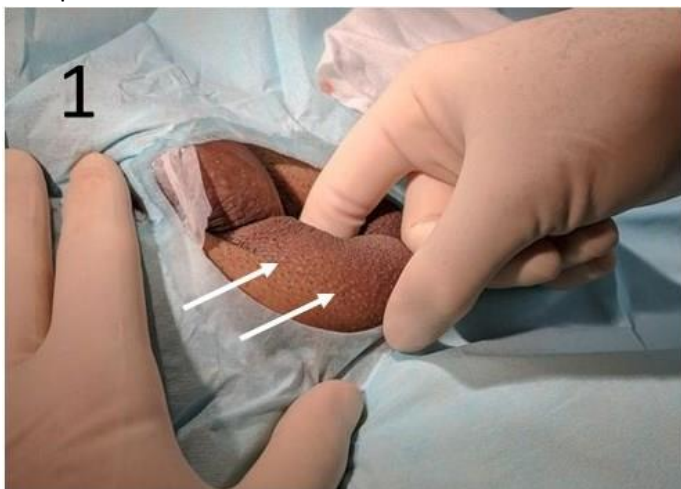5

6

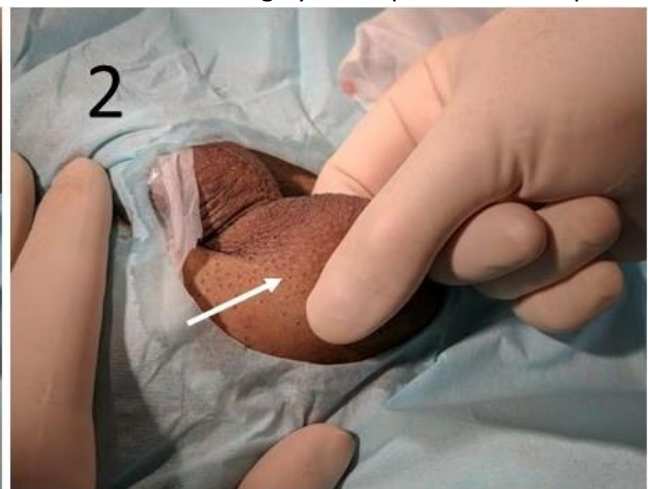


Roll the vas onto your left middle finger as it replaces your right thumb on the lateral scrotal wall (4). Then bring your left thumb in to replace your right index finger (5). Bring the left index finger forward and you'll be in the usual NSV position (6).

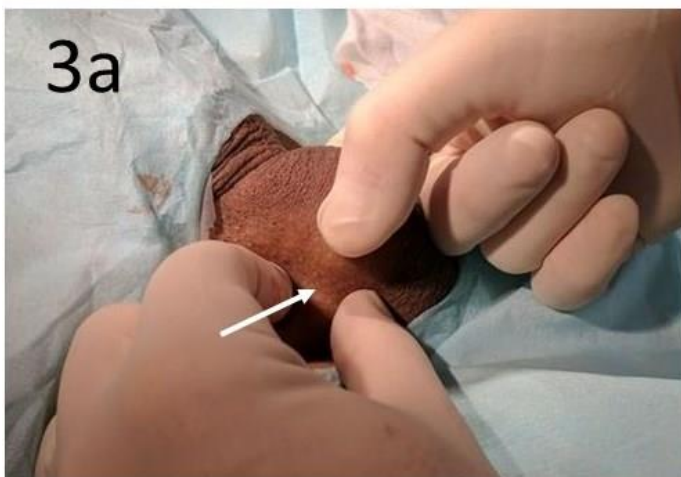The next photos are from the side rather than from below. The numbers should roughly correspond to the steps.



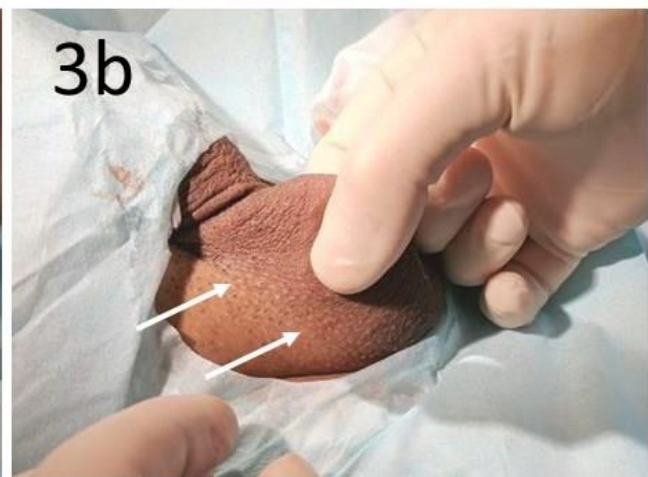1



2

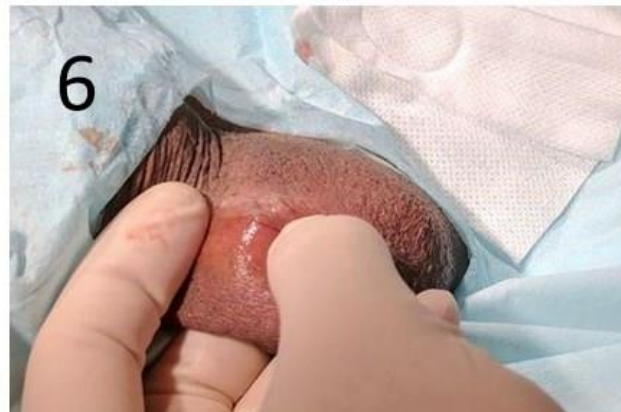
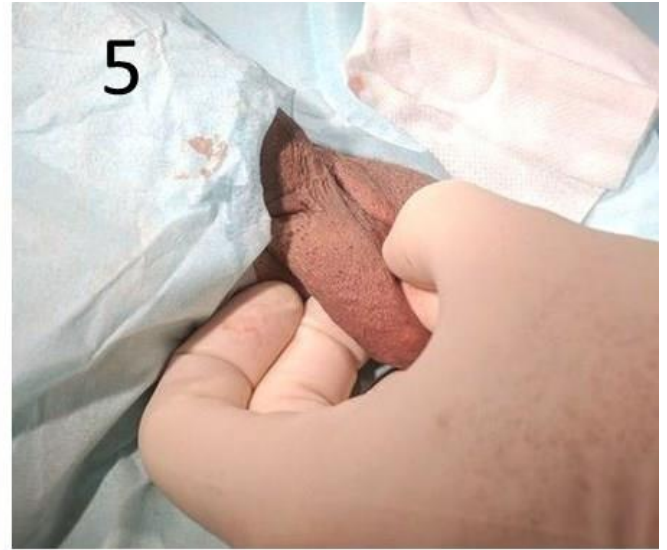
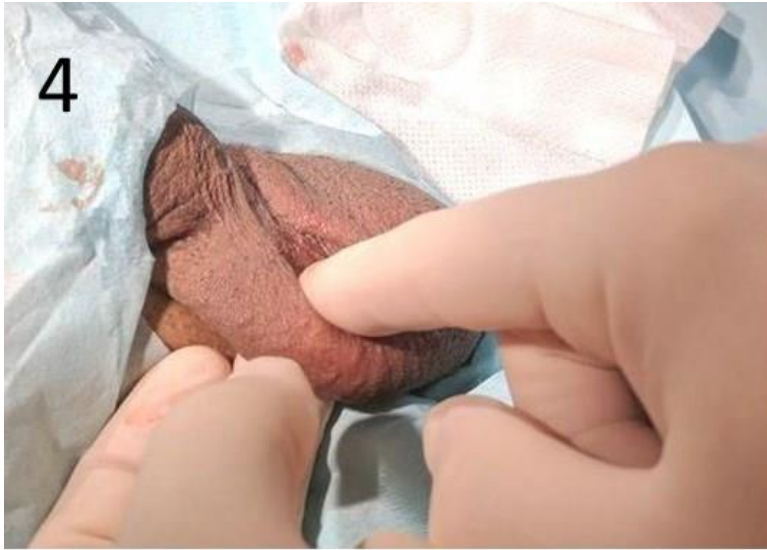3a



3b

In the last photos, you can see the line between thin scrotal skin and thick para-scrotal skin (arrows) being pushed posteriorly with the left thumb and index finger. This enables the operator to grasp the as within thin scrotal skin.



Again, the left third finger goes in to replace the right thumb and then the left thumb takes over from the right index finger. When the left index finger comes forward to push back the skin at the peno-scrotal junction, the operator has the vas in the classic 3-finger NSV fixation grasp.

At this point, poke (and stretch) a hole in the skin over the vas with your NSV dissecting clamp and insert the ring clamp through the hole to secure the vas within the NSV ring clamp. I find it easier to encircle the vas with the ring clamp if I first create “pockets” medial and lateral to the vas with the NSV dissecting clamp. The tips of the NSV ring clamp can now fall into these pockets to encircle the vas while the vas is pushed into the ring clip with the tip of the right third finger, a maneuver facilitated by contraction of the flexor digitorum profundus muscle to bend the right third DIP joint (green lines and arrows).

