

NO-SCALPEL VASECTOMY

An Illustrated Guide for Surgeons

Third Edition



ENGENDERHEALTH

Improving Women's Health Worldwide

© 2003 EngenderHealth. All rights reserved.
440 Ninth Avenue, New York, NY 10001 U.S.A.
Telephone: 212-561-8000
Fax: 212-561-8067
e-mail: info@engenderhealth.org
www.engenderhealth.org

First edition printed 1992
Second edition printed 1997

This publication was made possible, in part, through support provided by the Office of Population, U.S. Agency for International Development (AID), under the terms of cooperative agreement HRN-A-00-98-00042-00. The opinions expressed herein are those of the publisher and do not necessarily reflect the views of AID.

Figures 1, 4, 8, and 27 are adapted from: Li, S. Q., et al. 1991. The no-scalpel vasectomy. *Journal of Urology* 145(2):341-344. Used by permission.

Figures 3, 6, and 7 are adapted from: Li, P. S., et al. 1992. External spermatic sheath injection for vasal nerve block. *Urology* 39(2):173-176.

The two figures that appear in the section "Alternative" on page 38 are based on drawings provided by Dr. Apichart Nirapathpongporn. Used by permission.

ISBN 1-885063-34-2

Printing: Automated Graphic Systems, Inc.

Printed in the United States of America. Printed on recycled paper.

Library of Congress Cataloging-in-Publications Data

No-scalpel vasectomy : a training curriculum for surgeons.--3rd ed.
p. ; cm.

Revisions for the third edition were made by Dr. Mark Barone et al.

Includes bibliographical references.

ISBN 1-885063-34-2

1. Vasectomy. I. Barone, Mark.

[DNLM: 1. Vasectomy--methods. 2. Anesthesia--methods. 3. Preoperative care--methods. WJ 780 N739 2002]

RD585.5.N6 2002

617.4'63--dc21

2002192868

Contents

Preface to the Third Edition	vii
Acknowledgments	ix
Introduction	1
Facilities	5
Warm room temperature needed to relax the scrotum	5
Instruments and Supplies	7
Preoperative Preparation	11
Counseling and informed consent	11
Preoperative history and examination	11
Preparing the client for surgery	12
Securing the penis	12
Cleaning the operative area	12
The surgical scrub	13
Draping the operative field	13
Optional: Administering a preoperative tranquilizer	13
Anesthesia	15
Preparing for anesthesia; selecting the anesthetic and supplies	16
The three-finger technique: Isolating the right vas	17
Raising the skin wheal	18
Creating the vasal block: Right vas	20
The three-finger technique: Isolating the left vas	21
Creating the vasal block: Left vas	23
Pinching the skin wheal	24
If the client feels pain after surgery begins...	24

Surgical Approach and Occlusion of the Vasa 25

Holding the ringed clamp	25
Applying the ringed clamp to the scrotal skin and underlying right vas: The tight-skin technique	26
Elevating the underlying right vas	29
Puncturing the scrotal skin	29
Spreading the tissues	32
Delivering and elevating the right vas	35
Grasping the vas with the ringed clamp	39
Puncturing and stripping the sheath	41
Occluding the right vas	43
Ligating and excising the right vas	43
Creating fascial interposition	46
Isolating the left vas before occlusion	50
Applying the ringed clamp to the scrotal skin and underlying left vas	51
Delivering, elevating, and occluding the left vas	51
Dressing the wound	51
Postoperative care and instructions	52

Appendix:

World Health Organization (WHO) eligibility criteria for vasectomy procedures	55
--	-----------

References	59
-----------------------------	-----------

Figures

- 1** Ringed clamp 7
- 2** Dissecting forceps 8
- 3** Cross-section of the spermatic cord 15
- 4** The three-finger technique: Isolating the right vas 17
- 5** Raising the skin wheal 18
- 6** Side view of the skin wheal 19
- 7** Advancing the needle parallel to the vas within the external spermatic fascial sheath toward the inguinal ring 20
- 8** The three-finger technique: Isolating the left vas 22
- 9** Anesthesia technique: Deep infiltration of the left vas 23
- 10** Pinching the skin wheal 24
- 11** Holding the ringed clamp, with the palm up 25
- 12** Grasping the vas with the ringed clamp, extracutaneously 27
- 13** Pressing the tips of the ringed clamp onto the scrotal skin overlying the right vas 28
- 14** Lowering the handles of the ringed clamp to elevate the vas 29
- 15** Pressing the index finger lightly downward to tighten the scrotal skin just ahead of the tips of the ringed clamp and over the anesthetized area 30
- 16** Piercing the skin with the medial blade of the dissecting forceps 31
- 17** Inserting both tips of the dissecting forceps into the puncture site 33

- 18 Spreading the tissues to make a skin opening twice the diameter of the vas 34
- 19 Piercing the wall of the vas with the tip of the lateral blade of the dissecting forceps 35
- 20 Rotation of the dissecting forceps, Part 1 36
- 21 Rotation of the dissecting forceps, Part 2 36
- 22 Releasing the ringed clamp before elevating the vas with the dissecting forceps—ringed clamp open, but still in place 37
- 23 Grasping a partial thickness of the elevated vas 39
- 24 Grasping a partial thickness of the elevated vas at the crest of the loop, with only the ringed clamp attached 40
- 25 Puncturing the sheath with one tip of the dissecting forceps 41
- 26 Inserting both tips of the dissecting forceps into the punctured sheath 42
- 27 Opening the dissecting forceps to strip the sheath 42
- 28 Steps in performing vasectomy by ligation with excision 44
- 29 Steps in completing vasectomy by fascial interposition 45
- 30 The completed fascial interposition, with the stump of the prostatic end outside the fascial sheath and the stump of the testicular end inside the fascial sheath 47
- 31 Cautery with a sharp needle electrode 48
- 32 Cautery with a blunt wire inserted into the hemitransected vas 48
- 33 Sometimes a segment of the vas is removed following cauterization 49
- 34 Isolating the left vas before occlusion 50
- 35 Dressing the wound 52

Preface to the Third Edition

Vasectomy has long been a safe, effective, easy-to-perform method of contraception for men. Throughout its history, people have been trying to find ways to make the procedure simpler. In 1974, Dr. Li Shunqiang developed the no-scalpel vasectomy technique, and in 1986, EngenderHealth (then known as AVSC International), in cooperation with Dr. Li, began to introduce the technique to the rest of the world.

EngenderHealth first published *No-Scalpel Vasectomy: An Illustrated Guide for Surgeons* in 1992. The manual has since become one of EngenderHealth's most successful publications, with thousands having been distributed. Meanwhile, EngenderHealth has trained doctors in more than 40 countries in the no-scalpel vasectomy technique. In the United States alone, more than 1,000 doctors have been directly trained by EngenderHealth, and hundreds more have been trained by those we trained.

Because of the ongoing demand for this publication, we are publishing this third edition. We have updated the content and made changes in the illustrations to provide a more detailed representation of the anatomy. We have expanded the description of ligation and excision with fascial interposition, as evidence indicates that fascial interposition significantly improves the effectiveness of vasectomy by ligation and excision and leads to a more rapid decrease in sperm counts after vasectomy (Sokal et al., 2001). We have also expanded the discussion of cautery and have updated the Appendix to reflect eligibility criteria for vasectomy published by the World Health Organization (WHO) in 2000. Overall, what we have now is an even more timely version of an already useful book.

However, as good as it is, we continue to feel that this book alone is not sufficient preparation to perform no-scalpel vasectomy. We strongly recommend that those interested in the technique get hands-on training from a skilled provider. In addition to this

third edition, EngenderHealth has updated its training curriculum for no-scalpel vasectomy. For information about the curriculum or about training in no-scalpel vasectomy, contact EngenderHealth at: 212-561-8000 (phone); info@engenderhealth.org (e-mail); or www.engenderhealth.org.

I believe that this revised guide will continue to be an important resource for making vasectomy more accessible and acceptable, and of higher quality, throughout the world.

Roy Jacobstein, M.D., M.P.H.
Medical Director, EngenderHealth

Acknowledgments

The first edition of this book was written by Betty Gonzales, former deputy director of the Medical Division of EngenderHealth (then known as AVSC International); Shelby Marston-Ainley, former assistant director of EngenderHealth's National Division; Dr. Gilberte Vansintejan, former medical technology advisor for EngenderHealth's Medical Division; and Dr. Philip Shihua Li, who was then a consultant to EngenderHealth and a research investigator for the Population Council. Dr. Li is now director of microsurgical research and training at the Center for Male Reproductive Medicine and Microsurgery, Cornell Institute for Reproductive Medicine, Weill Medical College at Cornell University in New York. Dr. Philip Shihua Li has performed more than 5,000 no-scalpel vasectomy procedures and is a former student and co-worker of Dr. Li Shunqiang, the originator of the no-scalpel technique.

The original illustrations for the first and second editions of this book were created by David Rosenzweig. Illustrations for the third edition were prepared by Laura Pardi Duprey.

Many individuals and organizations contributed to this book. EngenderHealth expresses special thanks to Dr. Li Shunqiang, director of the Chongqing Family Planning Scientific Research Institute, who originated the technique; Dr. Li provided unwavering support for the development of this guide and constructive comments about its content.

EngenderHealth is grateful to the expert team who visited China in 1985 and first brought word of no-scalpel vasectomy to other countries. They were Dr. Mahmoud Fathalla, Egypt; Dr. Phaitun Gojaseni, Thailand; Dr. Marc Goldstein, United States; Dr. Douglas Huber, United States; Dr. Jack Lippes, United States; Keekee Minor, United States; Dr. Mary Rauff, Singapore; and Dr. John Sciarra, United States.

Terrence W. Jezowski, now vice president for development at EngenderHealth, provided the impetus needed to get the first edition of this book produced. Lynn Bakamjian, currently senior vice president for programs at EngenderHealth, developed the proposal for the project.

The following persons read the manuscript of the first edition and provided helpful suggestions: Dr. Arnold M. Belker, United States; Dr. Joseph E. Davis, United States; Dr. Marcos Paulo de Castro, Brazil; Dr. Jesús de los Rios, Colombia; Dr. Richard Fadil, United States; Dr. Marc Goldstein, United States; Hugo Hoogenboom, United States; Dr. Stuart S. Howards, United States; Dr. Douglas Huber, United States; Dr. Arnaldo Kormes, Brazil; Dr. Apichart Nirapathpongporn, Thailand; Dr. T. Rand Pritchett, United States; Dr. David Stockton, United States.

Dr. Amy E. Pollack, president of EngenderHealth; Libby Antarsh, former regional director of EngenderHealth's programs in Central Asia, Eastern Europe, and Russia; and Dr. Zein Khairullah, former senior associate in EngenderHealth's Medical Division, also reviewed the manuscript.

Dr. Charles Carignan, then the medical director of EngenderHealth, was responsible for all revisions for the second edition of this book. Pamela Beyer Harper, then director of communications, edited the second edition of the guide, and Renée A. Santhouse designed the book.

The revisions for the third edition of this book were made by Dr. Mark Barone, senior manager, Research; Dr. S. S. Bodh, senior program associate, India Country Office; Dr. Carmela Cordero, deputy medical director; and John M. Pile, senior manager, Family Planning Services. Michael Klitsch, senior writer/editor, edited the third edition of the guide.

The following EngenderHealth staff members participated in the design and production of the third edition: Karen Landovitz, manager, Publishing Program; Anna Kurica, production supervisor; Virginia Taddoni, graphics specialist; and Margaret Scanlon, editorial assistant.

Funding for this book was provided by the U. S. Agency for International Development and by individual EngenderHealth members.

Introduction

The purpose of this guide is to provide physicians with an easy-to-use reference for learning about the no-scalpel approach for vasectomy. This book provides a detailed description of each step of the approach, plus drawings illustrating the various steps. Physician-trainees may use it during their training for study and for later reference to further develop proficiency in the technique. Trainers who are using EngenderHealth's *No-Scalpel Vasectomy Curriculum* to teach the technique to other physicians will use this guide as a reference text.

The guide has been designed primarily to assist two audiences: (1) experienced vasectomists around the world who want to change from the traditional incisional technique to the no-scalpel approach, and (2) doctors who have never performed vasectomy and who want to begin to provide vasectomy services using the no-scalpel technique.

No-scalpel vasectomy is a refined approach for isolating and delivering the vas that uses vasal block anesthesia; the technique requires unique surgical skills, including new ways to handle special instruments. Recommended methods of occlusion are presented on pages 43 to 49. Because of the innovative features of no-scalpel vasectomy, EngenderHealth recommends that any doctor interested in learning the approach receive hands-on training with a well-qualified and experienced trainer.

Hands-On Training Recommended

From field experience in the United States, EngenderHealth has learned that even experienced vasectomists have difficulty teaching themselves the no-scalpel technique. Manipulating the special instruments requires manual skills and eye-hand coordination that are different from those used in conventional vasectomy. The skills can be learned with hands-on, supervised training, but even then they take time and practice to master.

A case in the United States illustrates the need for hands-on training. A group of experienced vasectomists attended a one-day group orientation on no-scalpel vasectomy that consisted of a lecture, observation of the procedure, and limited practice with a scrotal model. They then received the special no-scalpel instruments and returned to their practices to begin using the technique. Three months later, an EngenderHealth trainer evaluated the physicians' operating performance. The doctors understood and performed key elements of the procedure adequately; they stated that they had mastered about 80% of the technique without hands-on instruction. Yet the procedures observed by the trainer still resulted in too much bleeding; benefits of the no-scalpel technique were therefore diminished. Consequently, the EngenderHealth trainer provided hands-on training to help the surgeons fully master the no-scalpel technique.

No-scalpel vasectomy was developed and first performed in China in 1974 by Dr. Li Shunqiang of the Chongqing Family Planning Scientific Research Institute, located in Sichuan Province. At that time, vasectomy was unpopular with Chinese men, and tubal occlusion was the predominant method of voluntary sterilization. Today in Sichuan, vasectomy outnumbers tubal occlusion by a ratio of four to one; in the rest of China, tubal occlusion outnumbers vasectomy by five to one. More than 10 million Chinese men have already undergone no-scalpel vasectomy.

Under the sponsorship of EngenderHealth, an international team of experts visited Dr. Li Shunqiang in 1985 and observed his refined vasectomy technique. They were convinced that the technique should become the standard approach for vasectomy. One of the team members, Dr. Phaitun Gojaseni, introduced the no-scalpel technique in Thailand upon his return, while another member of the team, Dr. Marc Goldstein, performed the first no-scalpel vasectomy in the United States.

Based upon the findings of the international team, EngenderHealth recommended that training in the no-scalpel approach to the vas should be provided to doctors in other countries and that this would be facilitated if the instruction could take place outside of China. EngenderHealth's initial work in no-scalpel

History of No-Scalpel Vasectomy

vasectomy focused on experienced vasectomists in large ongoing vasectomy services (Huber, 1989). In 1986, Dr. Li Shunqiang and Dr. Goldstein traveled to Bangkok to work with experienced vasectomists from Bangladesh, Nepal, Sri Lanka, and Thailand. Dr. Apichart Nirapathpongporn of Thailand was trained at this time. Dr. Goldstein and Dr. Apichart then trained other surgeons in their home countries. Clinical training then expanded to other countries. In several countries in Africa, where vasectomy is just being introduced, doctors who have never performed vasectomy are now being trained only in the no-scalpel technique.

Clinical Findings No-scalpel vasectomy results in fewer hematomas and infections than does conventional incisional vasectomy (Table 1).

TABLE 1. Percentage of vasectomies in which infection or hematoma or bleeding occurred, by type of vasectomy and study

Study	No. of vasectomies	% with infections	% with hematoma or bleeding
Incisional vasectomy			
Philp, Guillebaud, & Budd, 1984	534	1.3	4.5
Kendrick et al., 1987	65,155	3.5	2.0
Nirapathpongporn, Huber, & Krieger, 1990	523	1.3	1.7
Alderman, 1991	1,224	4.0	0.3
Sokal et al., 1999	627	1.3	10.7
No-scalpel vasectomy			
Nirapathpongporn, Huber, & Krieger, 1990	680	0.2	0.3
Li et al., 1991	179,741	0.9	0.1
Li et al., 1991	238	0.0	0.0
Viladoms Fuster & Shihua Li, 1994	400	0.0	0.0
Arellano Lara et al., 1997	1,000	0.0	2.1
Kumar et al., 1999	4,253	0.047	0.07
Sokal et al., 1999	606	0.2	1.7

Source: Adapted from Pollack & Barone, 2000.

Men undergoing no-scalpel vasectomy reported less pain during the procedure and early in the follow-up period than did men having an incisional vasectomy, and also reported earlier resumption of sexual activity after surgery (Skriver, Skovsgaard, & Miskowiak, 1997; Sokal et al., 1999).

Neither conventional nor no-scalpel vasectomy is time-consuming. However, there are reports of decreased operating time when skilled providers use the no-scalpel approach (Li et al., 1991; Nirapathpongporn, Huber, & Krieger, 1990). For example, in the United States, a 40% reduction in operating time has been reported with no-scalpel vasectomy (Li et al., 1991).

1 Facilities

Vasectomy can be performed in almost any facility (WHO, 1988). There are a few minimum requirements to providing high-quality services:

- A waiting area with a toilet (The waiting area may also serve as a recovery area.)
- A private space for counseling
- An examination room for the preoperative assessment and follow-up examination
- A clean room for surgery, equipped with a comfortable, clean table for the client and a good light source

In most countries, no-scalpel vasectomy, like conventional vasectomy, is an outpatient procedure performed in an office or clinic.

Warm Room Temperature Needed to Relax the Scrotum

The temperature of the room is *critical* because it affects the cremasteric and the dartos muscles. The room must be warm, even though a cooler temperature may be more comfortable for the physician.

By relaxing the scrotum, a warm room facilitates the following:

- Manipulation of the vas by using the three-finger technique (see pages 17 and 21 to 22 for a description)
- Fixation of the vas under the median raphe of the scrotum
- Isolation of the vas from the relaxed spermatic cord
- Reduction of operating time
- Reduction of complications

The temperature of the operating room should be at least 70 to 80 degrees F (approximately 20 to 25 degrees C). If additional warmth is needed to relax the scrotum, a heat lamp or warm towels may be used.

2 Instruments and Supplies

The no-scalpel technique requires two instruments specially designed by Dr. Li Shunqiang.

1. The **extracutaneous ringed forceps** is a type of clamp used to fix the vas deferens (*Fig. 1*). For the sake of clarity, the term **ringed clamp** will be used throughout this manual. Throughout the operation, the surgeon uses the ringed tip of this instrument to encircle and to grasp the vas, without injuring the skin. The clamp grasps the vas both extracutaneously and directly. This instrument comes in three ring sizes: 3.0 mm, 3.5 mm, and 4.0 mm. These different diameters accommodate different thicknesses of vasa and scrotal skin.

FIGURE 1. Ringed clamp

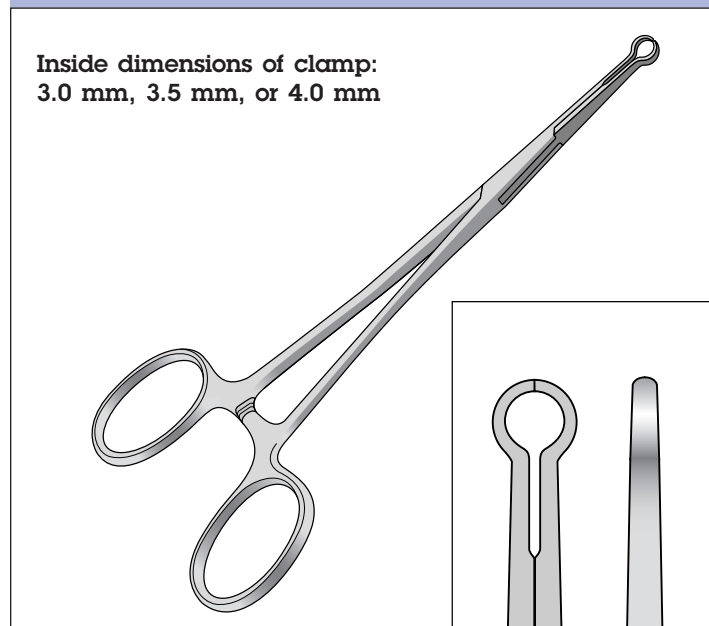
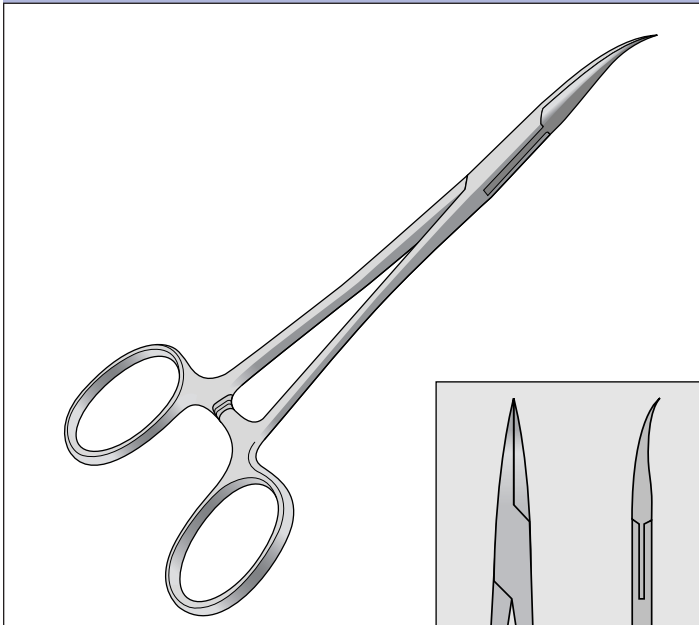


FIGURE 2. Dissecting forceps



2. The dissecting forceps (*Fig. 2*) is similar to a curved mosquito hemostat, except that the tips are sharply pointed. It is used to puncture the scrotal skin, to spread the tissues, to dissect the sheath, and to deliver the vas deferens. The dissecting forceps can also be used to grasp the vas while a ligature or cautery is applied for occlusion. Because the instrument is a modified hemostat, it can be used to control bleeding. Throughout this manual, the term **dissecting forceps** will be used to refer to this instrument.

Additional instruments and supplies needed for no-scalpel vasectomy are:

- A 10-cc syringe with a 1½-inch, 25- or 27-gauge needle (U.S. system). The syringe and needle are used to infiltrate the local anesthetic, both for the skin wheal and the vasal block anesthesia (see Chapter 4).
- Straight scissors, to cut the vasa deferentia and ligatures.
- Supplies for vasal occlusion (for example, ligature material or a cautery unit).

Table 2 presents a complete list of instruments and supplies needed for no-scalpel vasectomy.

TABLE 2. Instruments and supplies needed for no-scalpel vasectomy

Instruments

- Ringed clamp
 - Dissecting forceps
 - Straight scissors
-

Supplies

- Adhesive tape and gauze for positioning the penis away from the surgical field (optional)
 - Scissors for clipping any scrotal hair that would interfere with the procedure
 - Soap and water or antiseptic agents for the surgical scrub (*see page 13*)
 - Alcohol rinse (recommended if plain soap is used for the surgical scrub)
 - Sterile gloves
 - Nonirritating antiseptic solution for cleaning the operative area (*see page 12*)
 - Sterile drapes
 - 10-cc syringe with a 1½-inch, 25- or 27-gauge needle (U.S. system)
 - 1% or 2% lidocaine without epinephrine^a
 - Supplies for vasal occlusion according to the surgeon's preference (examples: a cautery unit; chromic catgut or nonabsorbable silk or cotton for ligation)
 - Sterile gauze
 - Adhesive tape or Band-Aid for dressing the wound
 - Scrotal support for the man to wear after the procedure (optional)
-

^a Synonyms and proprietary names for generic terms used in this book are given below. Proprietary names are in brackets:

lidocaine = lignocaine = [Xylocaine]
epinephrine = adrenaline

3 Preoperative Preparation

Counseling and Informed Consent

Before any vasectomy is performed, the client must receive appropriate information and counseling and give his informed consent. Before performing the procedure, check again with the client to be sure he wants no more children and wishes to proceed with the sterilization procedure.

Preoperative History and Examination

The preoperative history and examination may be done on the day of surgery or a few days before. A medical history should be taken. The preoperative physical includes examination of the local operative area and other examinations and tests as indicated. Laboratory tests are usually not necessary, but if you suspect any clinical abnormality, you will need access to basic laboratory facilities or to a referral center for laboratory examinations. Local skin infections or reproductive tract infections must be treated before vasectomy is performed.

The following are conditions requiring a delay or special precautions:*

- Local infection—including scrotal skin infection, active sexually transmitted infection (STI), balanitis, epididymitis, or orchitis
- Previous scrotal injury
- Systemic infection or gastroenteritis
- Large varicocele
- Large hydrocele
- Filariasis; elephantiasis
- Local pathological condition (e.g., intrascrotal mass, cryptorchidism, or inguinal hernia)
- Bleeding disorders
- Diabetes
- AIDS (HIV-positive status without AIDS is not a concern.)

*See Appendix for the WHO eligibility criteria for vasectomy procedures.

Many of these conditions can be treated, after which vasectomy can be performed. In cases where there is increased risk, you and the client must weigh the risks of the procedure against its benefits.

Before surgery, the client washes his genital area thoroughly with soap and water. During surgery, he wears clean clothing or a surgical gown. The man lies comfortably in a supine position on the table, possibly with a small pillow under his head.

Preparing the Client for Surgery

To make the operation easier to perform, position the penis away from the operative field. The surgical drape is usually adequate for securing the penis and keeping it away from the operative field. Some physicians secure the penis on the abdomen with tape and gauze, but this method may have the disadvantage of pulling the hair when the tape is removed. If the penis is anchored with tape, put the penis in a 12 o'clock position on the man's abdomen.

Securing the Penis

Shaving the surgical site is not recommended, as it produces small nicks and breaks in the skin where bacteria can grow and multiply, and thus increases the risk of postprocedure infection. If you believe that the scrotal hair is obstructing the small operative area, clip it while the client lies on the table. If, however, the site *must* be shaved: (1) use antimicrobial soap and water, or shave dry; and (2) shave immediately before the procedure, while the client is on the table.

Before cleaning the area, examine the scrotal area. Palpate the scrotum and vasa to assess the thickness of the scrotal skin and the diameter of the vasa.

Cleaning the Operative Area

Gently wash the scrotum with a warm antiseptic solution. Be sure to cleanse the area under the scrotum where your fingers will be placed. Also scrub the lower abdomen, the lower part of the penis, and the upper thighs. Warmed Betadine (povidone iodine) or chlorhexidine are the preferred agents. In hot climates, solutions at room temperature are usually adequate.

HINT: In cool climates, it may be necessary to warm the antiseptic solution.

The Surgical Scrub

No-scalpel vasectomy is a minor surgical procedure that requires aseptic procedures to prevent infection.

Wash and scrub your hands and forearms either with soap and water or preferably with antiseptic agents (chlorhexidine, iodophors, or hexachlorophene). Use a brush on all surfaces and under the fingernails. An alcohol rinse is recommended when plain soap and water are used for the scrub.

Wear a clean shirt or apron. A sterile gown, cap, and mask are optional.

Wear sterile surgical gloves. Change gloves between each case. If scrubbing is not feasible between each case because of the risk of skin irritation, scrub for three minutes every hour or at least after every four or five cases (whichever comes first) to prevent recolonization of the skin.

Draping the Operative Field

Cover the prepared area with a sterile fenestrated drape, and lift the scrotum through the drape's small window. A set of towels can be used as an alternative to the drape.

The window should be small enough to allow only the scrotum to be isolated. Everything else, from the client's chest to his knees, should be covered.

Also, cover a small instrument table with a sterile drape.

Optional: Administering a Preoperative Tranquilizer

HINT: Some doctors in the United States have found that oral tranquilizers administered preoperatively relax the muscle fibers of the scrotum, thus allowing the scrotal skin to be as thin as possible during vasectomy. This suggestion is particularly relevant for extremely nervous clients.

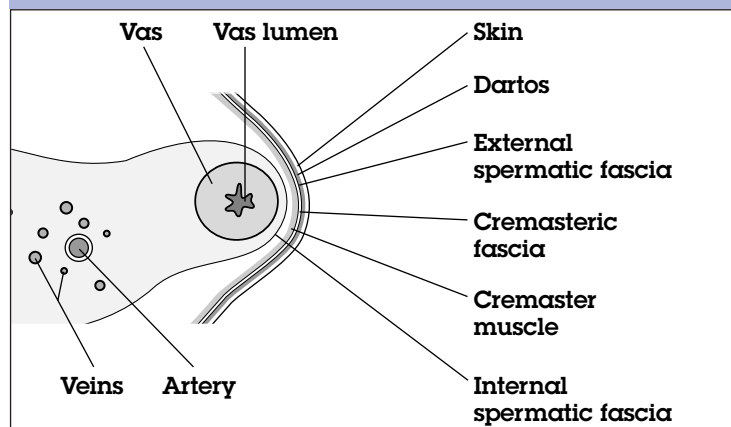
Note: Information in this section is adapted from: EngenderHealth, 2000.

4 Anesthesia

Good local anesthetic technique is essential for a pain-free vasectomy. It also prevents local hematoma and injury to the testicular vessels, which may result from multiple blind injections. Dr. Li Shunqiang's anesthesia procedure, which is described below, achieves both of these objectives and also has several other advantages. The technique, which involves a deep injection alongside the vas, creates a vasal nerve block. Conventional techniques anesthetize only the area around the skin-entry site. Injection of the anesthetic away from the vasectomy site in the direction of the inguinal ring helps make skin entry easier. Care is taken when injecting the lidocaine to keep the needle away from the internal spermatic fascia that enclose the testicular artery and veins (*Fig. 3*). Because the surgeon makes only a single needle puncture and one smooth injection for each vas, the risk of bleeding is reduced.

In a randomized trial comparing no-scalpel vasectomy to the conventional technique, men undergoing no-scalpel vasectomy with vasal block anesthesia reported experiencing less operative pain than did men undergoing conventional vasectomy (Sokal et al., 1999).

FIGURE 3. Cross-section of the spermatic cord



NOTE: The following instructions and accompanying illustrations are for the right-handed operator. Some left-handed operators report that they have found it helpful to use a mirror when viewing illustrations designed for right-handed operators.

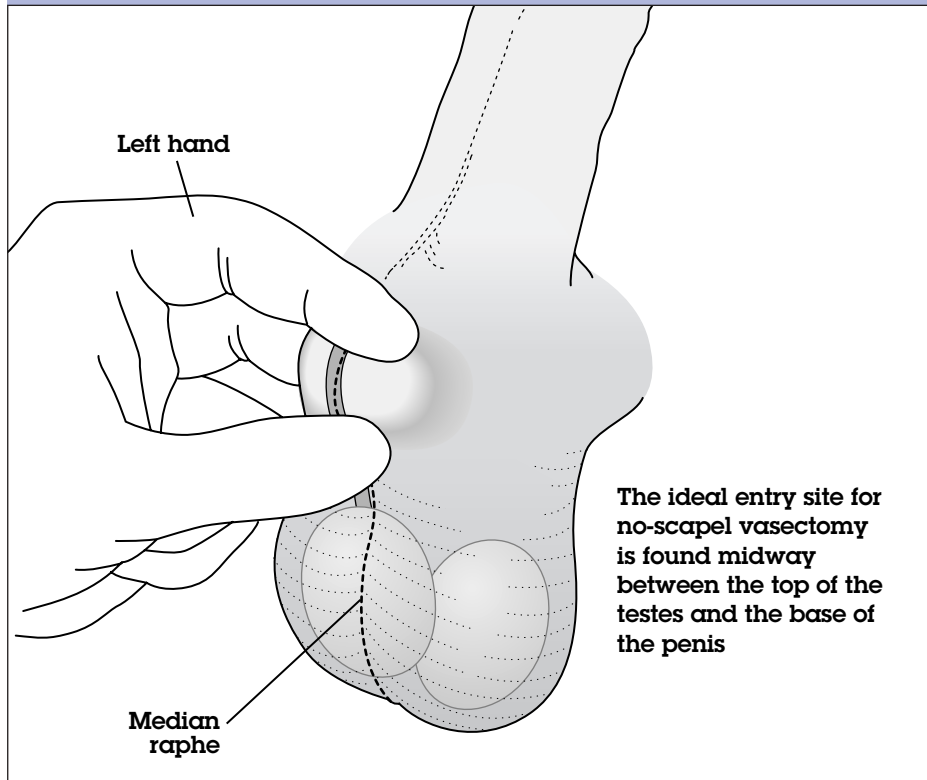
Prepare a syringe to administer 100 mg (10 cc 1% or 5 cc 2%) lidocaine without epinephrine. This amount should be sufficient for skin wheal and vasal block anesthesia in most clients. Attach a 1½-inch (or metric equivalent) small-gauge needle to the syringe. A 25- or 27-gauge needle is recommended, but a 22- or 23-gauge needle can also be used.

Epinephrine is not recommended because it contracts the blood vessels and results in less apparent bleeding at the time of surgery. It is best to be able to detect and control all bleeding *during* surgery to prevent hematomas from forming after the client leaves the surgical facility. If the lidocaine does not contain epinephrine, small bleeding sites are more likely to be detected and controlled during surgery.

The maximum individual dose of lidocaine without epinephrine should not exceed 4.5 mg/kg (2 mg/lb) of body weight. In general, it is recommended that the maximum total dose not exceed 300 mg (Medical Economics, 2002). This equates to 30 cc 1% or 15 cc 2% lidocaine without epinephrine.

Preparing for Anesthesia; Selecting the Anesthetic and Supplies

FIGURE 4. The three-finger technique: Isolating the right vas



**The Three-Finger
Technique:
Isolating
the Right Vas**

If you are right-handed, stand on the client's right side. (If you are left-handed, stand on the client's left side.) Place your left thumb approximately midway between the top of the testes and the base of the penis on the median raphe. With the middle finger of your left hand under the scrotum, palpate the vas and sweep it toward the raphe beneath your thumb. Hold the vas in position between the thumb and middle finger while placing your left index finger on top of the scrotum, slightly above the thumb (*Fig. 4*). Note that your fingers should be perpendicular to the vas. You will have created a "window" between your thumb and index finger through which you will make the puncture. Upward pressure from the middle finger, combined with downward pressure exerted by the index finger, creates a bend in the vas for easier entry. Maintain the three-finger hold as you anesthetize the right side.

Raising the Skin Wheel

The needle entry site is at the midline, over the vas deferens midway between the thumb and the index finger. Use only the tip of the needle to raise a superficial skin wheal, 1 to 1½ cm in diameter (*Fig. 5*). To raise the skin wheal, hold the syringe at approximately a 5- to 15-degree angle (*Fig. 6*), with the needle bevel facing up. Inject lidocaine into the dermis and subcutaneous tissues; 0.5 cc is usually adequate.

FIGURE 5. Raising the skin wheal

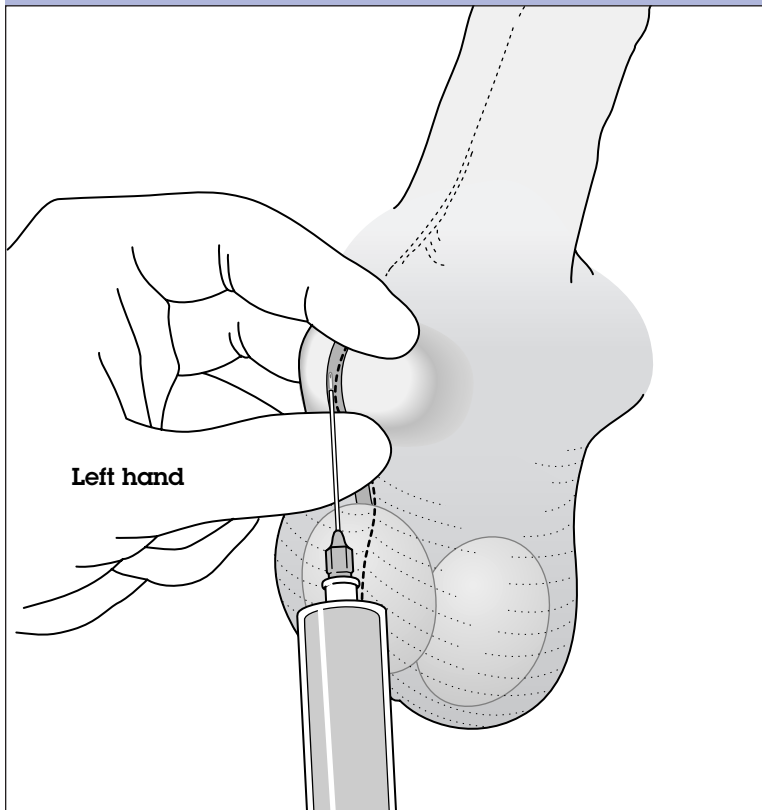
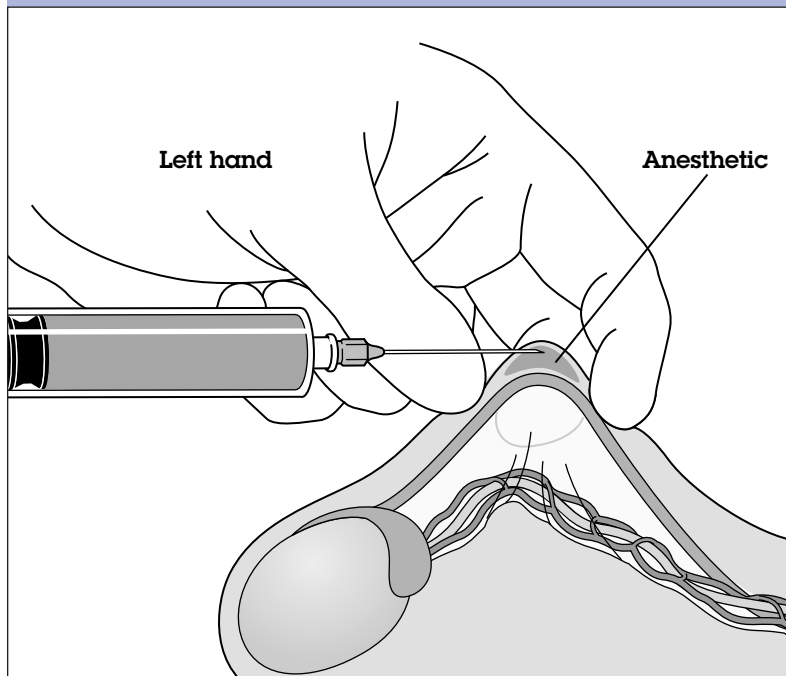


FIGURE 6. Side view of the skin wheal



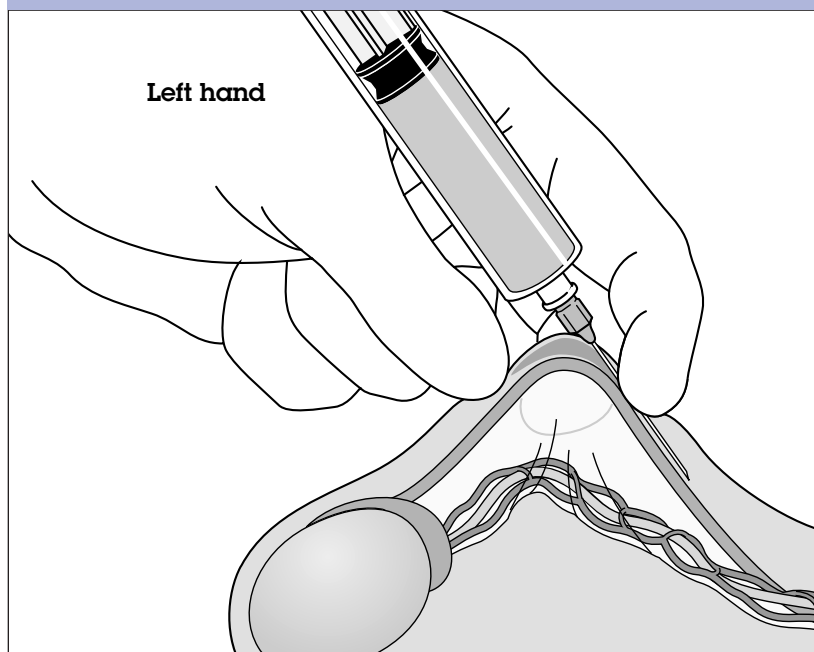
PITFALLS: Avoid two pitfalls when raising the skin wheal. First, do not inject the lidocaine too deeply. At this point in the procedure, you are anesthetizing only the scrotal skin. In the next step, you will create a vasal block that will anesthetize deeper tissues. Second, to avoid swelling around the vas at the puncture site, do not inject more than 1 cc of lidocaine. A persistent wheal will prevent the ringed clamp from closing properly around the vas.

Creating a vasal block is a critical difference from the way anesthesia has been traditionally administered for vasectomy. The steps described below create a vasal nerve block away from the operative site.

Creating the Vasal Block: Right Vas

After making the superficial skin wheal, advance the needle parallel to the vas within the external spermatic fascial sheath toward the inguinal ring (*Fig. 7*). Advance the full length of the needle, 1½ inches, without releasing any of the anesthetic. **Gently aspirate to ascertain that the needle is not in a blood vessel.** Without withdrawing the syringe, slowly inject 2 to 5 cc (depending on concentration) of lidocaine within the external spermatic fascial sheath around the right vas deferens.

FIGURE 7. Advancing the needle parallel to the vas within the external spermatic fascial sheath toward the inguinal ring



HINT: When the needle is in proper position and the injection is performed inside the external spermatic fascia, there is no resistance to the injection.

Remove the needle from the right sheath; do not inject lidocaine while withdrawing the needle.

**The Three-Finger
Technique:
Isolating
the Left Vas**

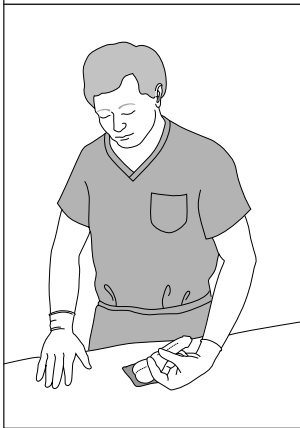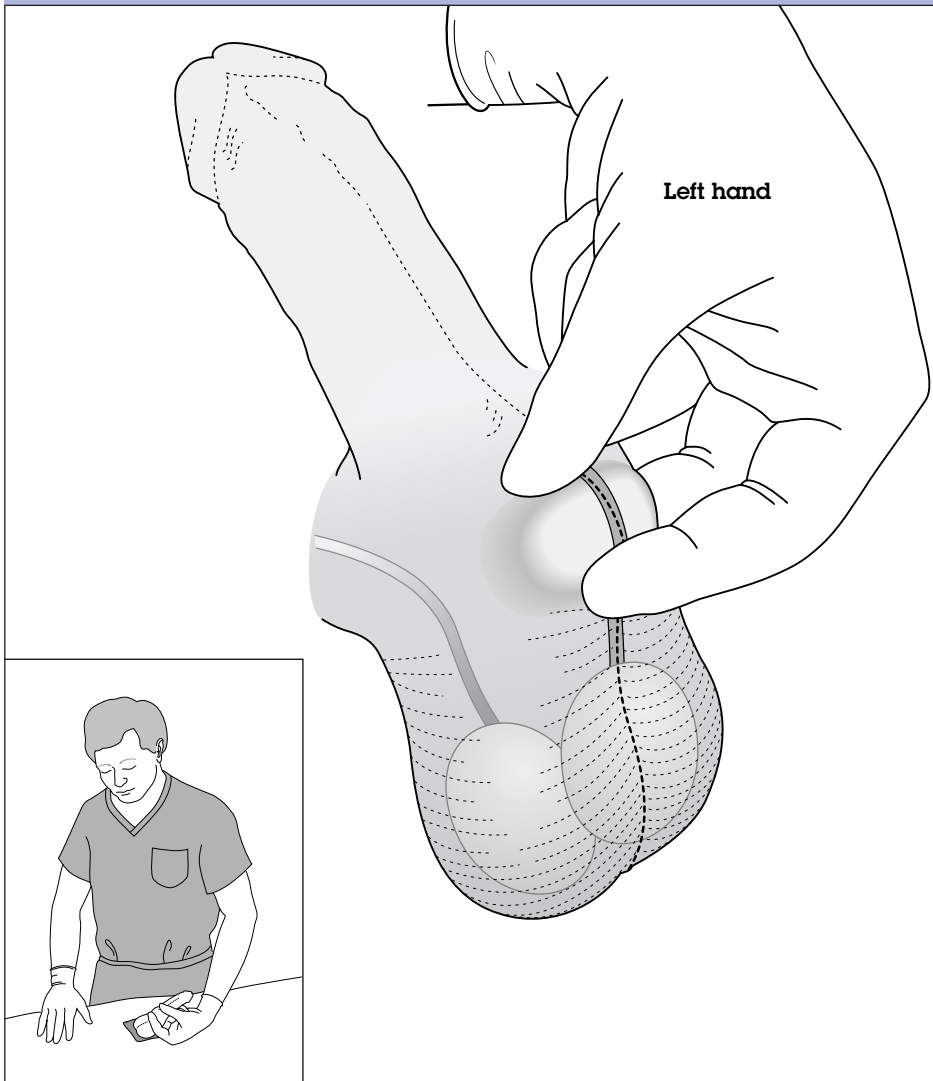
Anesthetize both sides before entering the scrotum and occluding the right vas.

HINT: To hold the client's left vas in the three-finger grip while standing on his right side, you will be more comfortable if you take a step toward the client's head and turn a bit to face his feet. To approach the vas from this lateral position, reach across the client's abdomen with your left hand.

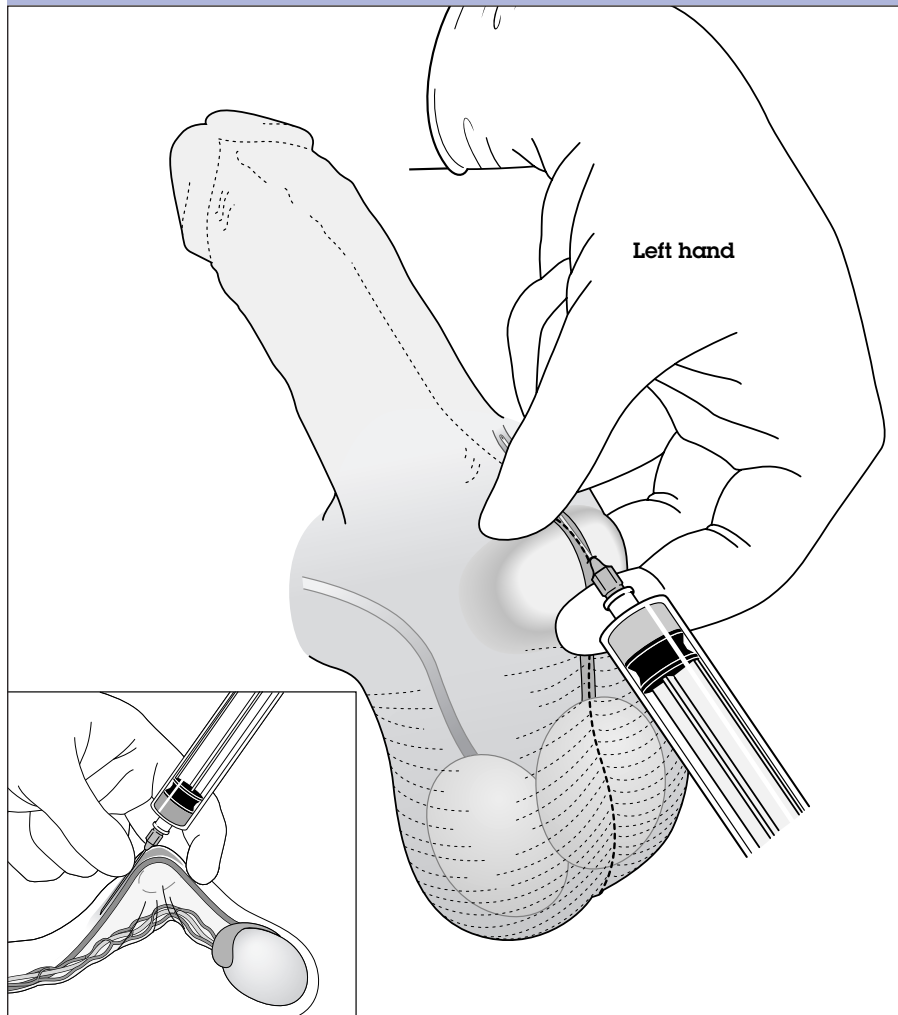
The next step will be to position the left vas under the anesthetized puncture site. To do this, begin by placing your thumb in the upper third of the scrotum while the index finger is in the middle third. (This is different from the three-finger hold on the right side.) As with the right side, position the middle finger beneath the scrotum to identify the vas and sweep it to the puncture site. Once again, use the middle finger to elevate the vas, while your thumb and index finger press downward to create a bend in the vas at a point directly under the puncture site. Now, however, the thumb is superior to the index finger (*Fig. 8, page 22*). Note the differences between Figures 5 and 8.

For a right-handed operator, isolating the left vas may be more difficult and awkward than was isolating the right vas. It may take time and practice to master. A left-handed operator will need to reverse these positions and thus may find isolation of the right vas more difficult.

FIGURE 8. The three-finger technique: Isolating the left vas



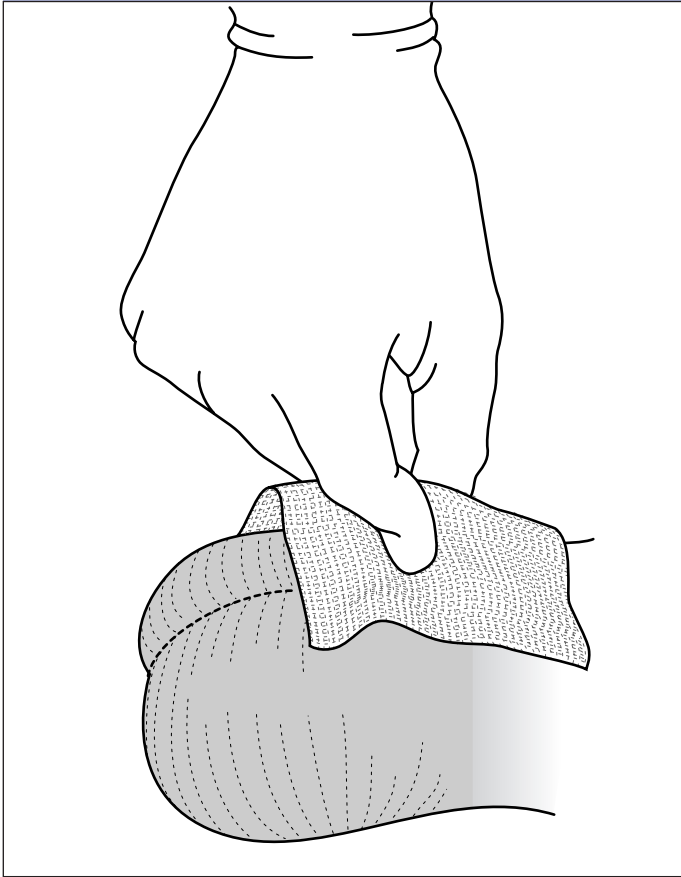
**FIGURE 9. Anesthesia technique:
Deep infiltration of the left vas**



**Creating
the Vasal Block:
Left Vas**

Reintroduce the needle through the same hole previously used; a second skin wheal is not needed. Advance the needle parallel to the left vas into the external spermatic fascia (*Fig. 9*). As with the right vas, inject 2 to 5 cc of lidocaine within the external spermatic fascial sheath around the left vas deferens.

FIGURE 10. Pinching the skin wheal



After removing the needle, gently pinch the skin wheal between the thumb and forefinger for a few seconds to reduce its size and to soften and thin the local tissues (*Fig. 10*).

PITFALL: Remember, a persistent wheal will prevent the ringed clamp from closing properly around the vas; gentle compression helps to reduce the size of the wheal.

If 2 to 5 cc of lidocaine has been injected into each side and the client still feels pain when the surgical procedure begins, repeat the vasa block on the painful side. Do not raise another skin wheal.

**Pinching
the Skin Wheal**

**If the Client
Feels Pain
After Surgery
Begins . . .**

5 Surgical Approach and Occlusion of the Vas

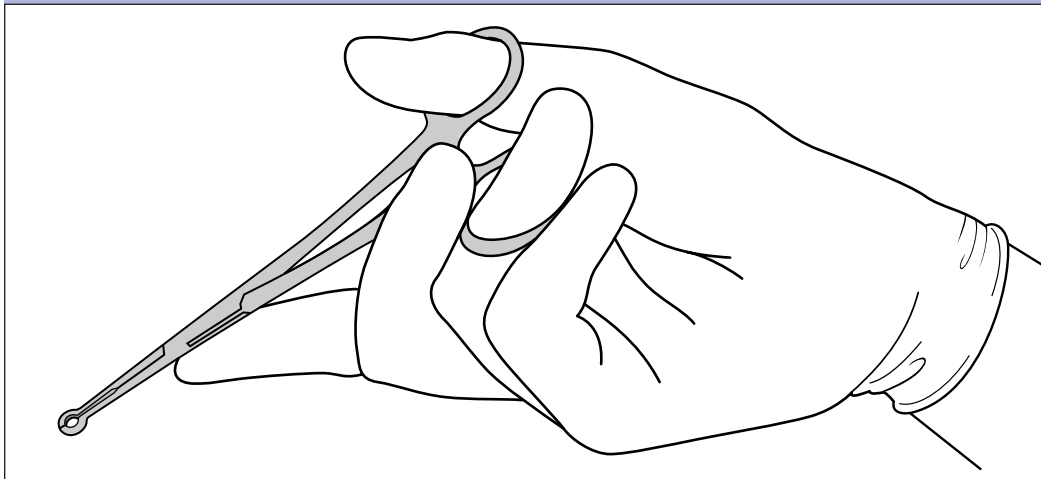
Although the no-scalpel technique is almost bloodless, an occasional superficial bleeder may be encountered. Ensure adequate hemostasis to help prevent the development of scrotal hematoma and subsequent risk of infection. Take all necessary precautions to avoid cross-contamination by strictly following the rules and guidelines for prevention of infection.

NOTE: The following instructions and accompanying illustrations are for a right-handed operator. Some left-handed operators report that they have found it helpful to use a mirror when viewing illustrations designed for right-handed operators.

Holding the Ringed Clamp

When holding the ringed clamp, it is important to remember three points. First, for the greatest control and accuracy, hold the ringed clamp with the palm facing up and the wrist extended (*Fig. 11*). Second, apply the clamp at a 90-degree angle perpendicular to

FIGURE 11. Holding the ringed clamp, with the palm up



the vas (*Fig. 12a*); the palm-up hand position helps make this easier to do. Third, hold the shaft of the ringed clamp in line with the axis of the vas—parallel to and directly over the vas (*Fig. 12c*).

PITFALL: If you fail to follow these three points, the clamp may not fix the vas completely (*Figs. 12b and 12d*), or it may grasp too much skin. The ringed clamp must encircle the entire vas.

Using the three-finger technique (as described on page 17 of the anesthesia chapter), tightly stretch the skin overlying the vas—where the needle entered for anesthesia infiltration. The skin should be as thin as possible. Apply the ringed clamp, as described earlier, with the shaft at a 90-degree angle perpendicular to the vas (*Fig. 12a*). Open the ringed clamp, and press the tips onto the skin immediately overlying the vas (*Fig. 13, page 28*). Apply upward pressure with the middle finger underneath the scrotum to resist the downward push of the ringed clamp and to press the vas from below into the ring. Slowly and gently close the clamp around the vas, up to the first click-stop.*

PITFALLS: Avoid two pitfalls when applying the ringed clamp. First, be sure to elevate the middle finger underneath the scrotum. Otherwise, the finger will give way under the downward pressure of the ringed clamp, and you will have difficulty stabilizing the vas. Second, do not grab too much skin with the ringed clamp. If you do, you will have difficulty dissecting and delivering the vas, and slight bleeding may occur. The skin should be stretched out over the vas just before the ring clamp is applied. If you grab too much skin, stabilize the vas with your left hand, then loosen the clamp slightly, without entirely

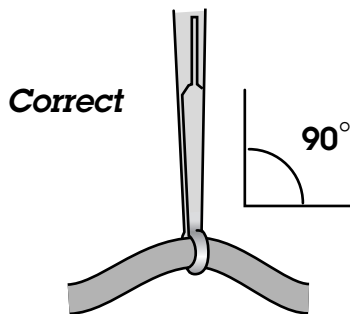
Applying the Ringed Clamp to the Scrotal Skin and Underlying Right Vas: The Tight-Skin Technique

*The cantilevered feature of the ringed clamp that is manufactured in China is specially designed to prevent damage to the scrotal skin even when the clamp is locked tightly.

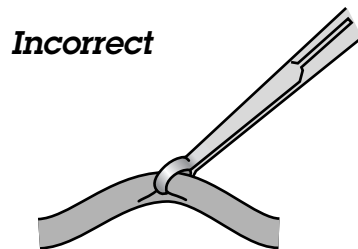
releasing it. Use the fingers of the left hand to ease some of the skin away from the clamp's hold, while retaining the clamp's grasp on the vas.

FIGURE 12. Grasping the vas with the ringed clamp, extracutaneously (scrotal skin not shown for clarity)

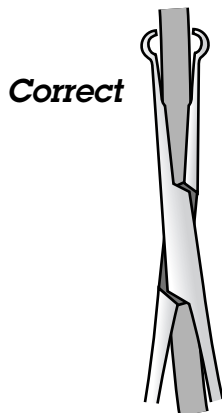
- a) Applying the ringed clamp at a 90-degree angle, perpendicular to the vas.



- b) If the ringed clamp does not grasp the vas at a 90-degree angle, the surgeon may grasp the vas incompletely.



- c) Holding the shaft of the ringed clamp in line with the axis of the vas (parallel to and directly over the vas).



- d) If the ringed clamp is not held parallel to the vas, the surgeon may grasp the vas incompletely.

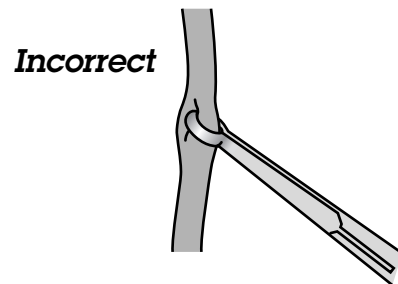
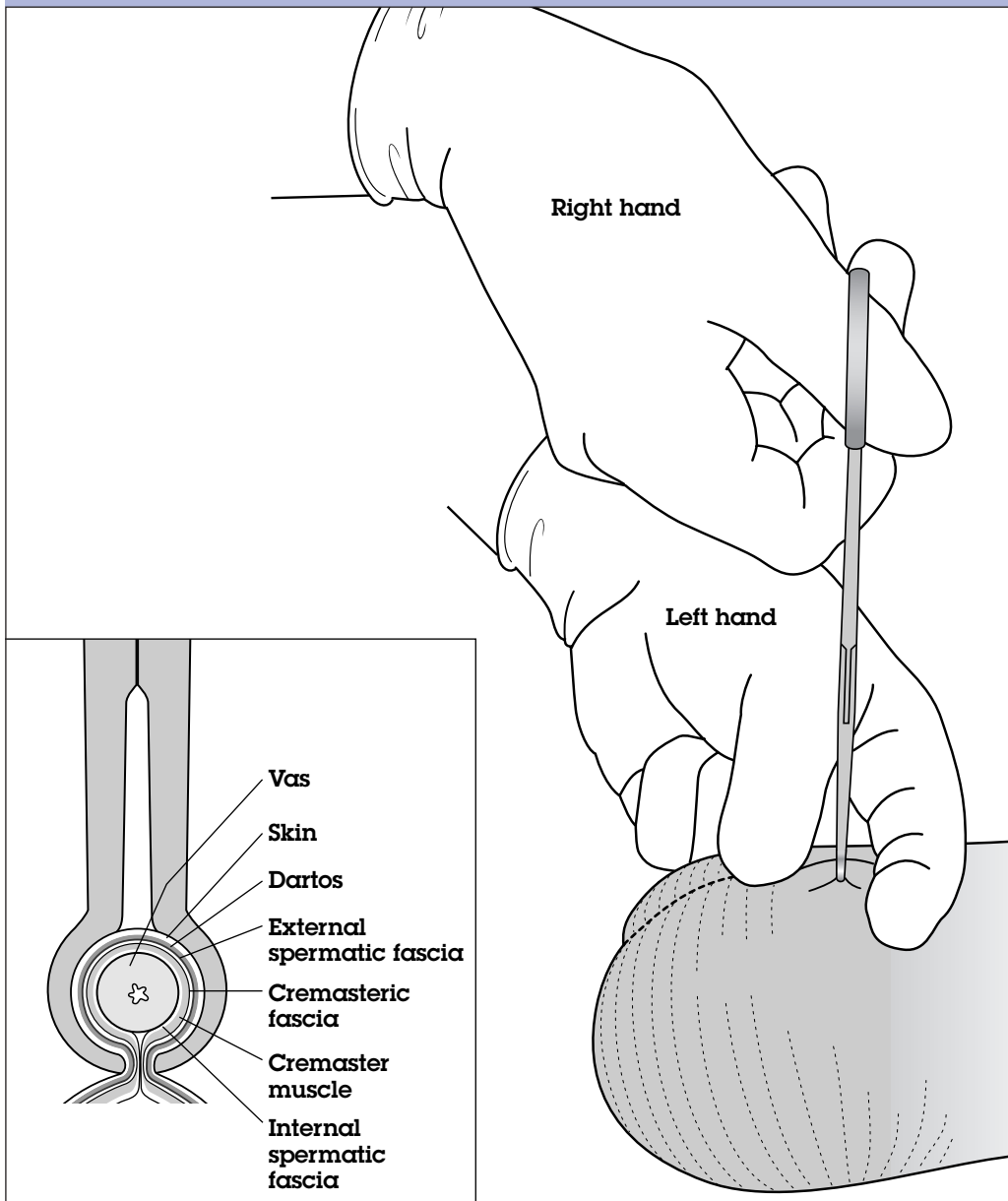


FIGURE 13. Pressing the tips of the ringed clamp onto the scrotal skin overlying the right vas



ALTERNATIVE: Instead of the tight-skin technique described on page 26, some surgeons apply the ringed clamp in a different way when they are first learning no-scalpel vasectomy. With the ringed clamp in the right hand, the surgeon gently pinches the scrotal skin with the ringed clamp, intentionally encircling more skin than is grasped with the tight-skin technique. With the left hand, the surgeon then eases out excess tissue from the tips of the ringed clamp. The surgeon may wish to use this alternative if he or she is having difficulty isolating only the vas.

Elevating the Underlying Right Vas

While the ringed clamp is still grasping the scrotal skin and the underlying right vas, transfer the instrument to your left hand. Then lower the handles of the ringed clamp, causing a bend in the vas (*Fig. 14*). This motion elevates the vas. Continue to keep the shaft of the clamp in line with the longitudinal axis of the vas.

Puncturing the Scrotal Skin

The skin should be punctured in the previously anesthetized spot, midway between the top of the testes and the base of the penis (*Fig. 4, page 17*). With the left index finger, press downward lightly to tighten the scrotal skin just ahead of the tips of the ringed clamp and over the anesthetized area (*Fig. 15, page 30*).

FIGURE 14. Lowering the handles of the ringed clamp to elevate the vas

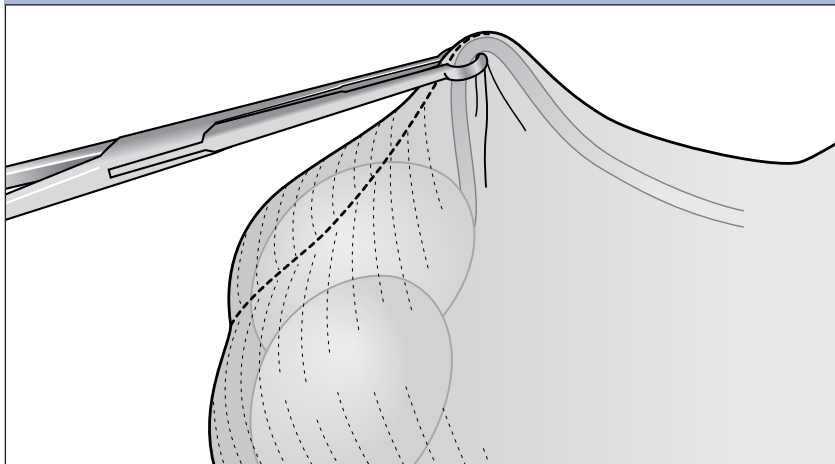
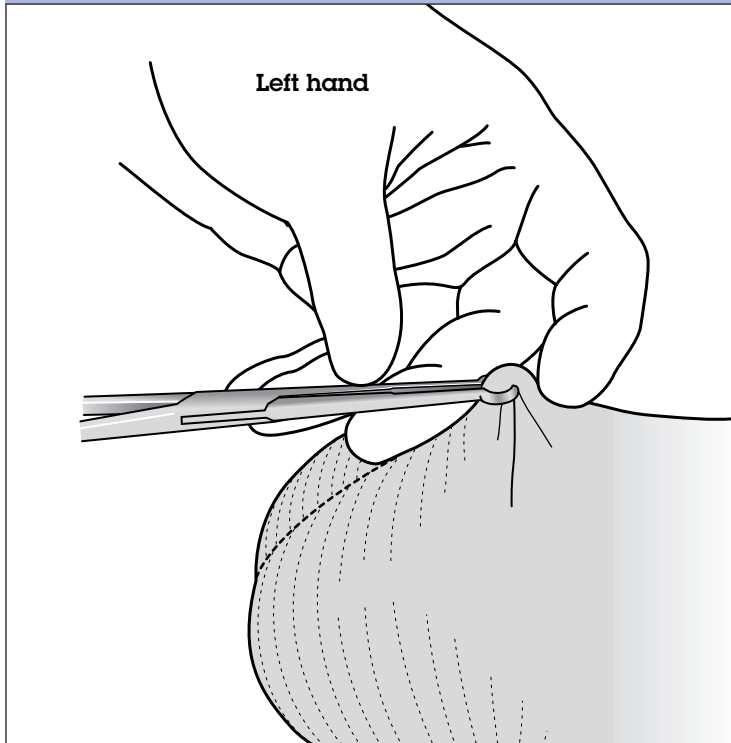
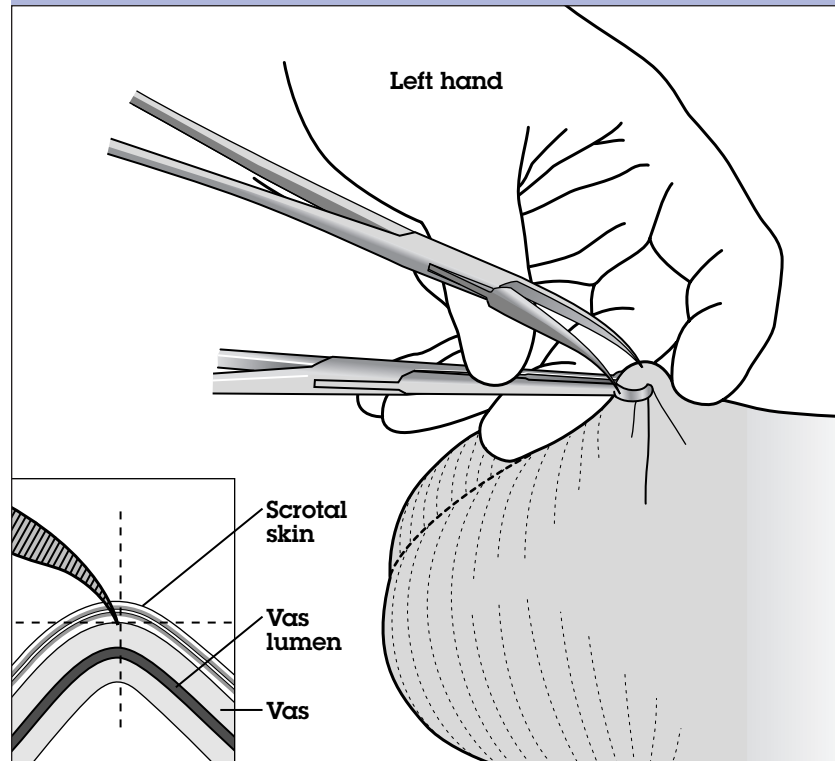


FIGURE 15. Pressing the index finger lightly downward to tighten the scrotal skin just ahead of the tips of the ringed clamp and over the anesthetized area



Hold the dissecting forceps in the right hand, points curved downward, in preparation for puncturing the vas. Hold the instrument so that there is a 45-degree angle between the closed tips of the forceps and the lumen. Then open the forceps; using only the medial blade (see box on page 32) of the forceps, pierce the scrotal skin **just superior to the upper edge of the ringed forceps**—where the vas is most prominent (*Fig. 16*). This piercing should result in a puncture of the midline of the vas, preferably at the point where the needle entered for anesthetic infiltration. When making the puncture, do not slowly push the dissecting forceps forward. Instead, use a quick, sharp, single movement to make a clear puncture of the skin down into the vas. Advance the medial blade of the forceps into the vas lumen.

FIGURE 16. Piercing the skin with the medial blade of the dissecting forceps



PITFALLS: Avoid three pitfalls when puncturing the scrotal skin. First, be sure to penetrate the anterior wall of the vas with the dissecting forceps. Otherwise, intact overlying fascia will prevent elevation of the vas out of the puncture wound. Second, if puncturing is too deep, transection of the vas might occur and the vas artery may be damaged, and bleeding will follow. Third, be sure to puncture the vas just superior to the upper edge of the ringed forceps; if the puncture is made in the tissue that is grasped by the ringed forceps, you will not be able to spread the tissues adequately (see next page).

After making the puncture, withdraw the medial blade of the dissecting forceps. Close the tips of the forceps. At the same 45-degree angle as before, insert both tips of the forceps in the same puncture hole, in the same line, and at the same depth as when you made the puncture with the single blade (*Fig. 17*).

The ringed clamp remains in place and locked while the skin is punctured.

(a) When puncturing the scrotal skin

If you are right-handed, the medial (inner) blade is the left blade. Conversely, if you are left-handed, the medial (inner) blade is the right blade. If you use the medial blade to pierce the scrotal skin, your hand will not obstruct your line of vision.

(b) When elevating the vas deferens

If you are right-handed, the lateral (outer) blade is the right blade. Conversely, if you are left-handed, the lateral (outer) blade is the left blade. If you use the lateral blade to pierce the wall of the vas deferens, you will easily be able to rotate the forceps and deliver the vas.

HINT: Right-handed operators should stand on the client's right side.

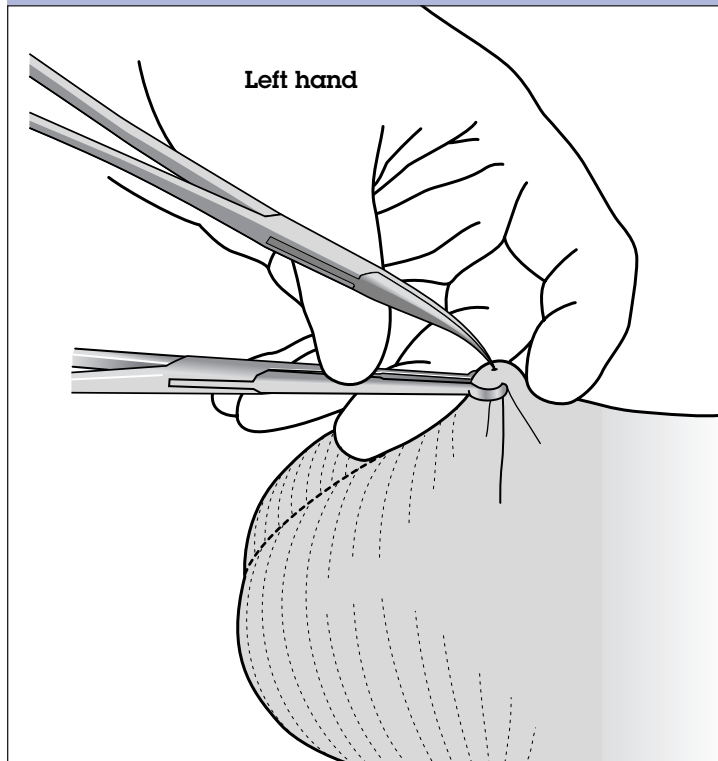
Conversely, left-handed operators should stand on the client's left side.

**Identifying
the Medial and
Lateral Blades
of the Dissecting
Forceps**

Gently open the tips of the dissecting forceps transversely across the vas, to create a skin opening twice the diameter of the vas (*Fig. 18, page 34*). In one motion, spread all layers of tissue from the skin to the vas deferens. The tips of the forceps should penetrate deeply enough to expose bare vas wall (see *Fig. 19, insert, page 35*). No harm is done if you enter the lumen. Be careful to keep the closed blades of the dissecting forceps parallel to the vas.

**Spreading
the Tissues**

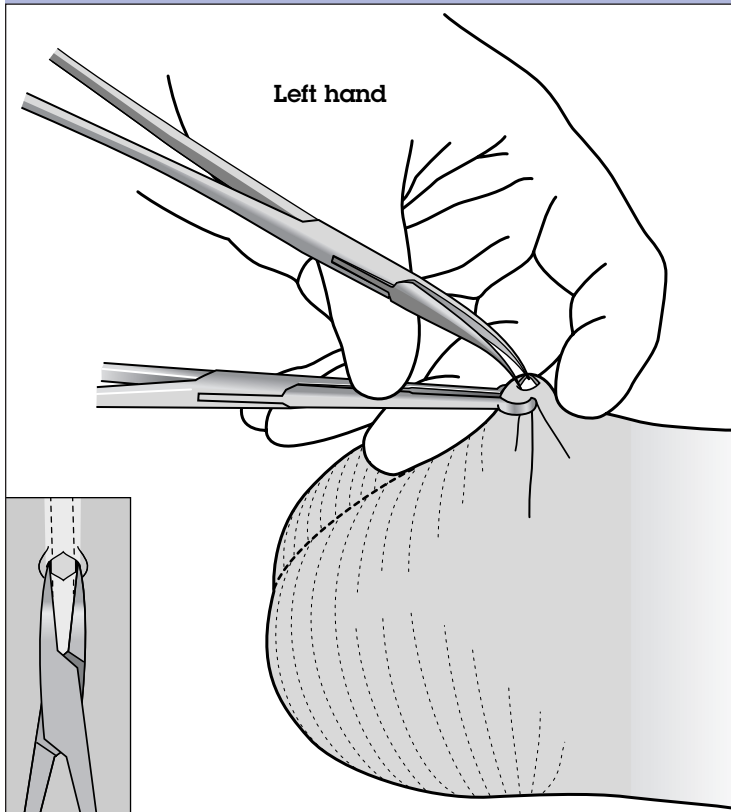
FIGURE 17. Inserting both tips of the dissecting forceps into the puncture site



The skin and vas sheath will remain stretched open after the tissues are spread. By contrast, the opening in the vas will close after spreading; as it closes, the puncture site in the vas may look like a longitudinal groove. The stretched opening in the skin and sheath, which should be twice the diameter of the vas, will enable you to lift out a loop of the vas.

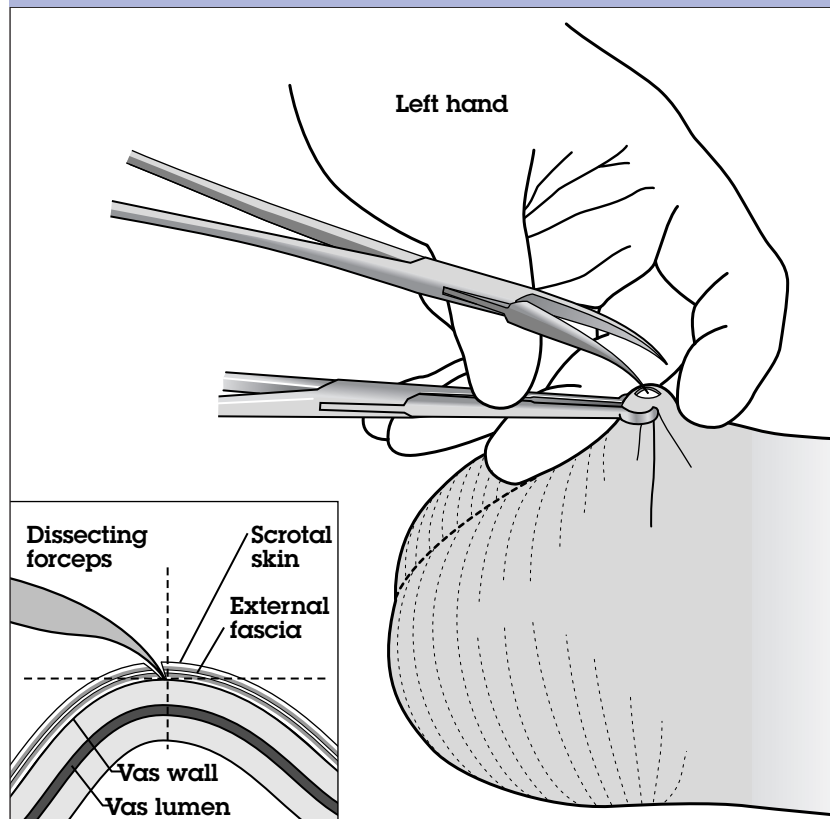
The ringed clamp remains in place and locked while the tissues are spread.

FIGURE 18. Spreading the tissues to make a skin opening twice the diameter of the vas



PITFALLS: Watch out for two pitfalls when spreading the tissues. First, if you fail to open the blades of the forceps transversely at a right angle to the vas, one blade could slip out of the puncture site. This could cause an unnecessary skin tear. Second, be sure to apply appropriate counterforce to prevent the dissecting forceps from slipping out of the puncture hole. Maintain depth of puncture, but do not push down further than the original puncture.

FIGURE 19. Piercing the wall of the vas with the tip of the lateral blade of the dissecting forceps



**Delivering
and Elevating
the Right Vas**

Remove the dissecting forceps from the puncture hole. With the tip of the lateral blade of the dissecting forceps facing downward, pierce the wall of the vas deferens at a 45-degree angle (*Fig. 19*). (See the box on page 32 for the definition of “lateral blade.”) Use of the lateral blade enables the operator to rotate his or her wrist more easily.

With the lateral blade skewering the vas and the ringed clamp still grasping the scrotal skin, rotate the handle of the dissecting forceps clockwise 180 degrees so the tips face upward, to deliver a loop of the vas deferens (*Figs. 20 and 21*). As you rotate the

FIGURE 20. Rotation of the dissecting forceps, Part 1

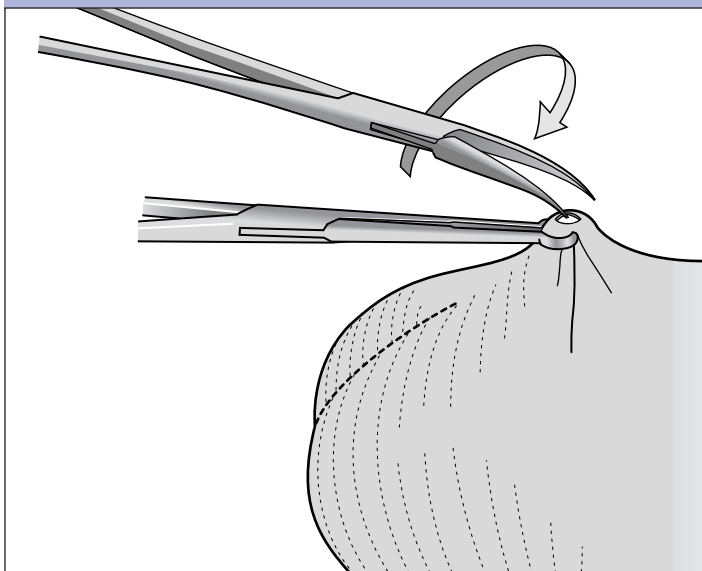
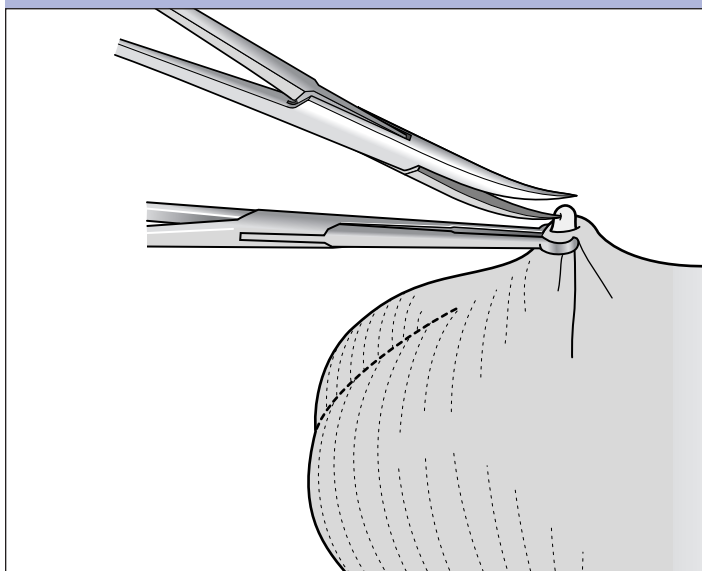


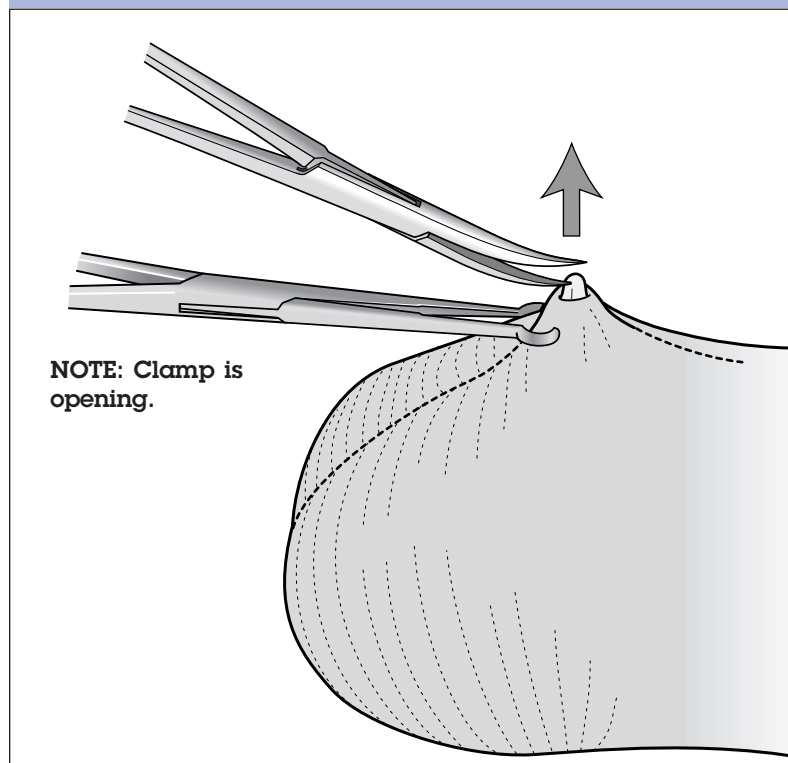
FIGURE 21. Rotation of the dissecting forceps, Part 2



dissecting forceps with the right hand, slowly release the ringed clamp with the left hand, thus allowing the forceps to elevate the vas through the puncture hole (*Fig. 22*). This simultaneous rotation with one hand and release of the ringed clamp with the other hand requires practice and coordination. At the beginning of the rotation, your hand will be palm-side down; after rotation, it will be palm-side up.

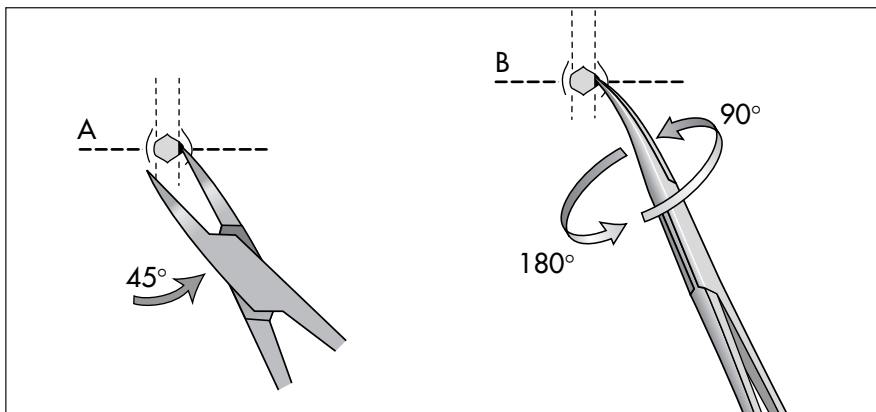
If the vas is difficult to deliver, more extensive spreading of the sheath may be required.

FIGURE 22. Releasing the ringed clamp before elevating the vas with the dissecting forceps—ringed clamp open, but still in place



ALTERNATIVE: There is an alternative way to deliver and elevate the vas; instead of skewering the vas with the dissecting forceps, the surgeon uses the forceps to grasp the bare vas directly. The following description is for the right-handed surgeon. The doctor begins by spreading the tissue as described on pages 32 to 34. But after stretching the opening in the skin and sheath, the surgeon does not remove the dissecting forceps from the puncture hole. Instead, the surgeon gradually withdraws the forceps, holding them in line with the longitudinal axis of the vas, until he or she can see the tips (facing downward) at the sides of the bare exposed vas.

The doctor then moves the right hand, which is holding the dissecting forceps, and the right elbow toward the right, away from his or her side, until the dissecting forceps are at about a 45-degree angle to the longitudinal axis of the vas (see A, below). This movement causes the medial blade to slip out of the wound, while the tip of the lateral blade continues to touch the right side of the vas.



Next, the doctor gently closes the tips of the forceps, grasping the right half of the bare vas, with the tips of the forceps facing to the side. The surgeon then starts to rotate the dissecting forceps in a clockwise direction about 90 degrees (see B, above); he or she stops rotating and checks to be sure that no fascia are between the tips of the forceps. The surgeon then further rotates the forceps, completing a 180-degree turn. After the rotation, the curved tips of the forceps are facing up. The rotational movement slightly elevates the vas out of the wound.

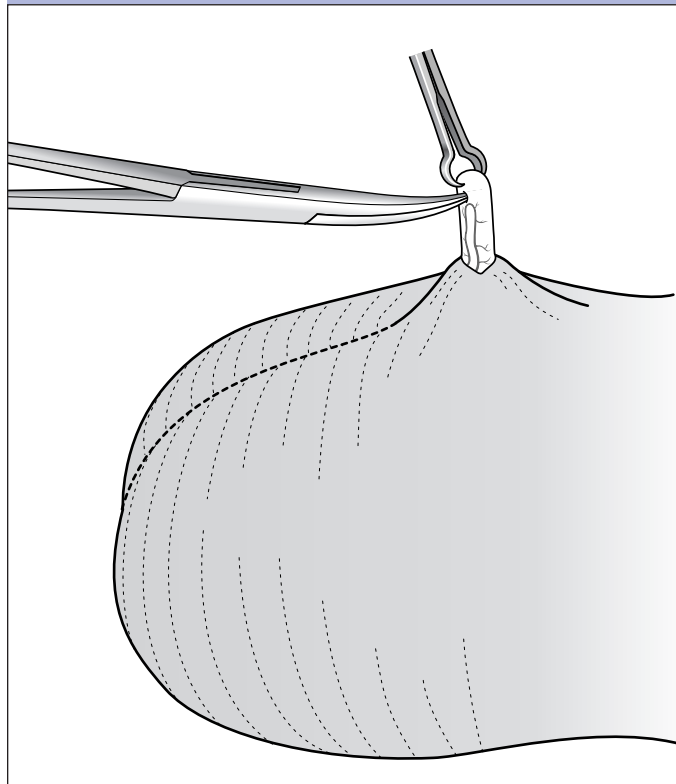
PITFALLS: With either technique described above, watch out for two pitfalls while delivering the vas. First, do not attempt to

deliver the vas while the ringed clamp is still locked; if you do, the vas may be severed. Second, if fascial tissue is caught between the tips of the dissecting forceps, you will not be able to rotate and elevate the vas.

**Grasping
the Vas
with the
Ringed Clamp**

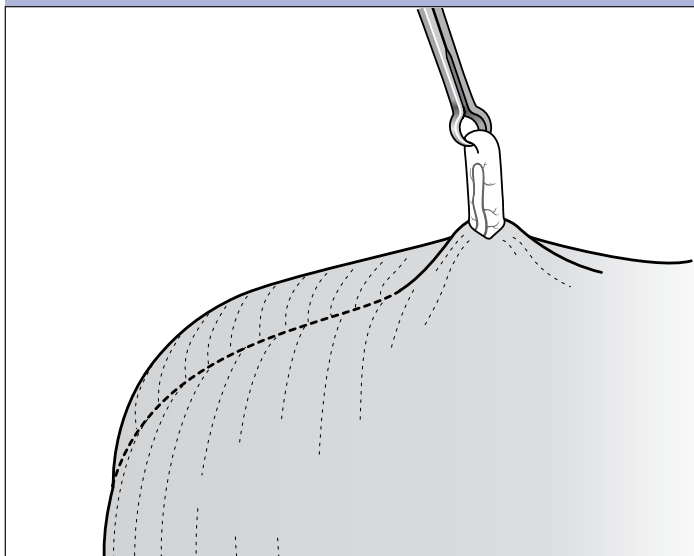
Once a loop of the vas has been delivered, gently close the dissecting forceps on the vas to prevent its slipping back into the scrotum while the ringed clamp is removed from the skin. Grasp a partial thickness of the loop of the vas with the ringed clamp. Sometimes you will see a groove on the vas—created when the vas was punctured (*Fig. 23*). After you have grasped a partial thickness of the vas, release the dissecting forceps.

FIGURE 23. Grasping a partial thickness of the elevated vas



PITFALLS: Watch out for three pitfalls when grasping the vas with the ringed clamp. First, be careful not to release the dissecting forceps until you have grasped a portion of the loop of the vas with the ringed clamp (*Fig. 23*). This will prevent the vas from slipping back into the scrotum. Second, to avoid damaging the vas artery, be sure to grasp the vas at the crest of the loop (*Fig. 24*). Grasping elsewhere leads to asymmetrical stripping of the sheath from the vas. Third, grasp only a partial thickness of the vas. If the ringed clamp is placed around the entire circumference of the vas, the vas could slip back into the scrotum when it is divided.

FIGURE 24. Grasping a partial thickness of the elevated vas at the crest of the loop, with only the ringed clamp attached



Puncturing and Stripping the Sheath

With one tip of the dissecting forceps (tips facing up), gently puncture the vas sheath just below the vas, taking care not to injure the vas artery (*Fig. 25*). Then remove the tip.

Close the tips of the dissecting forceps. Insert both tips (tips facing to the side) into the punctured sheath (*Fig. 26, page 42*).

Gently open the dissecting forceps (*Fig. 27, page 42*). Strip the sheath and surrounding tissues downward for at least a 1 cm length of vas. This is a longitudinal, not a transverse, motion.

Be careful to avoid blood vessels. Clamp or cauterize bleeders immediately. When checking for bleeding, pay particular attention to the abdominal segment of the vas, which is where bleeding from the vas artery could occur (a common reason for hematoma formation).

FIGURE 25. Puncturing the sheath with one tip of the dissecting forceps

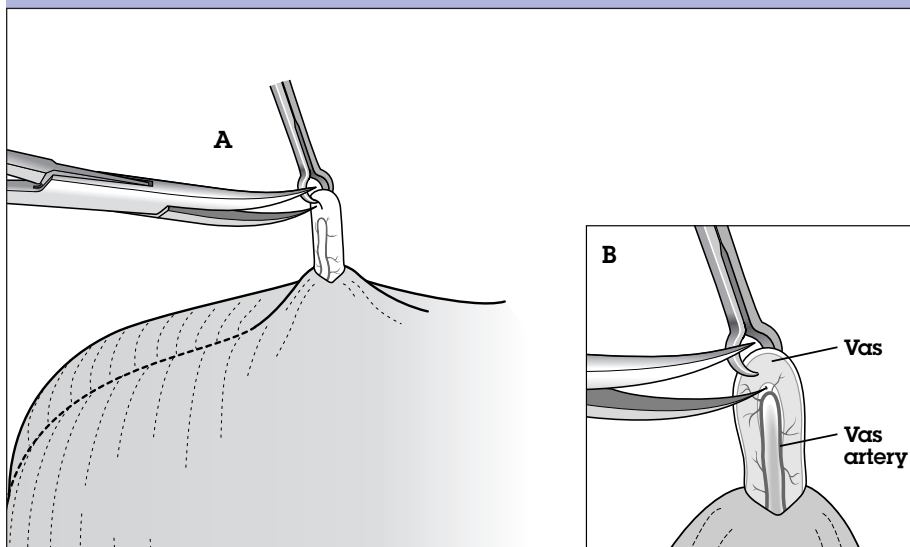


FIGURE 26. Inserting both tips of the dissecting forceps into the punctured sheath (tips facing to the side)

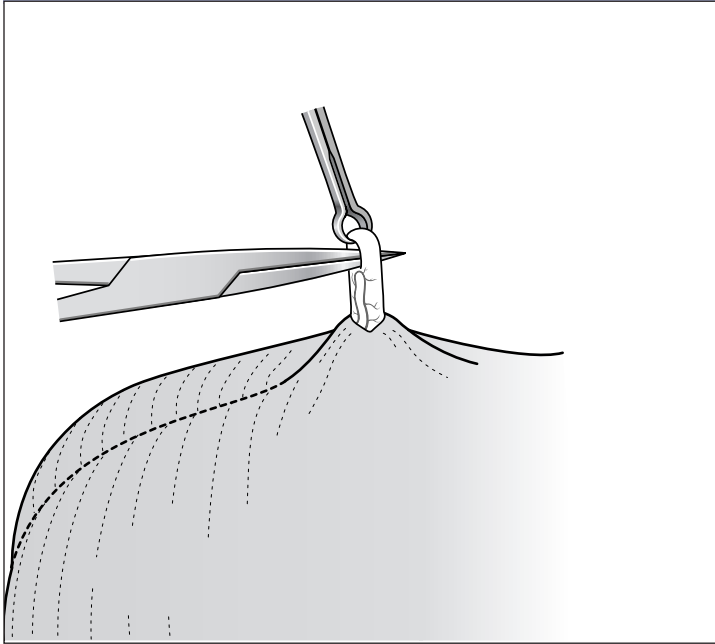
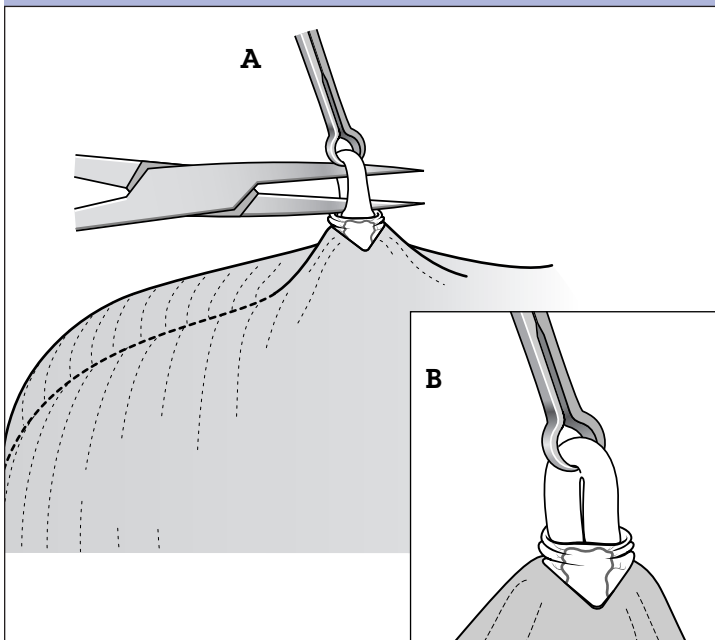


FIGURE 27. Opening the dissecting forceps to strip the sheath



Occluding the Right Vas

Now occlude the right vas. Remember, no-scalpel vasectomy is a **surgical approach for isolating and delivering the vas that uses conventional methods of vas occlusion**. Two recommended methods—ligation with excision and fascial interposition, and cautery—are described below.

Ligation with excision and fascial interposition. When used with ligation and excision, fascial interposition improves the effectiveness of vasectomy. Fascial interposition places a tissue barrier between the two cut ends of the vas, as a result of the operator's suturing (or securing with a clip) the thin layer of tissue that surrounds the vas (the fascial sheath) over one end of the vas. The stump of the prostatic (proximal) end is outside the fascial sheath and, when the vasectomy is completed, the stump of the testicular (distal) end is inside the fascial sheath.

Ligating and Excising the Right Vas

Before beginning ligation, make certain that all sheath and vasal vessels have been stripped away from the segment of vas to be occluded (*Fig. 28a, page 44*). Ligate the isolated vas at two points about 1.5 cm or more apart using two separate ligatures, first ligating the prostatic end of the vas and then the testicular end. After ligating the prostatic end, cut one end of the ligature, leaving a single uncut end of about 5 to 7 cm in length (*Fig. 28b*). **This will identify the prostatic end. The single uncut end of the ligature will be used to retrieve the vas, to facilitate fascial interposition.** Next, ligate the testicular end and leave both ends of the ligature about 5 to 7 cm in length (*Fig. 28c*).

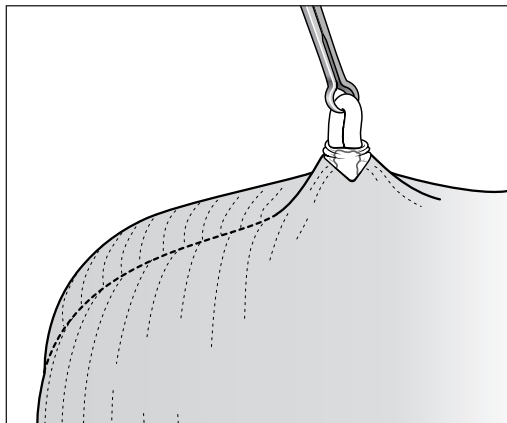
HINT: When excising the section of vas, leave an adequate stump at each end of the vas (approximately 3 mm), to ensure that the ligature does not slip off later.

Some operators use absorbable suture material such as chromic catgut; others prefer nonabsorbable silk or cotton. There have been no studies done to determine the best material for ligating the vas.

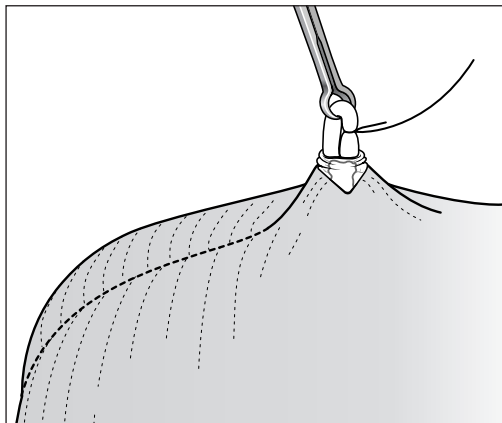
Excise up to 1 cm of the vas (*Fig. 28d*). When excision is completed, assure that both stumps are not

FIGURE 28. Steps in performing vasectomy by ligation with excision

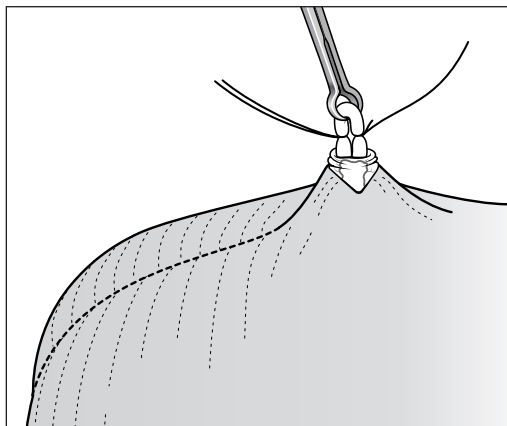
(a) Sheath and vasal vessels are stripped away from the part of the vas being occluded



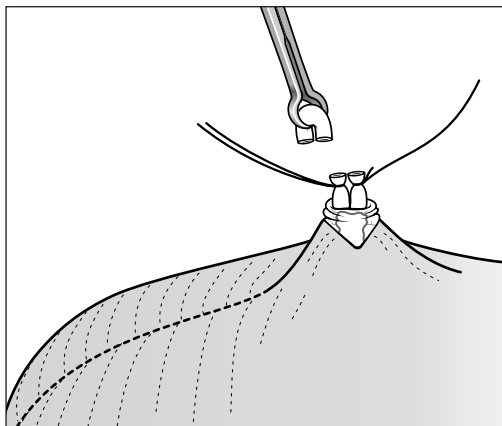
(b) The prostatic end of the vas is ligated, and one end of the ligature is cut



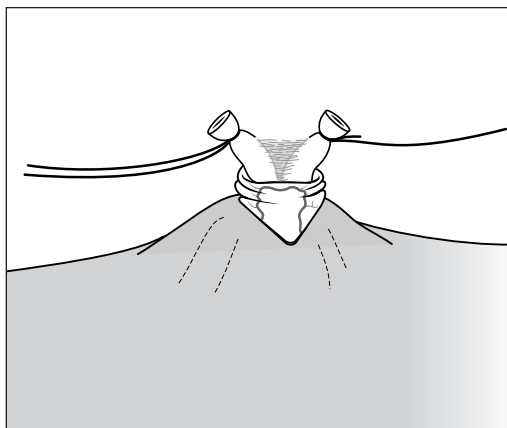
(c) The testicular end of the vas is ligated



(d) Up to 1 cm of the vas is excised



(e) Both stumps are separated by at least 1 cm



(f) The ligature at the testicular end is cut

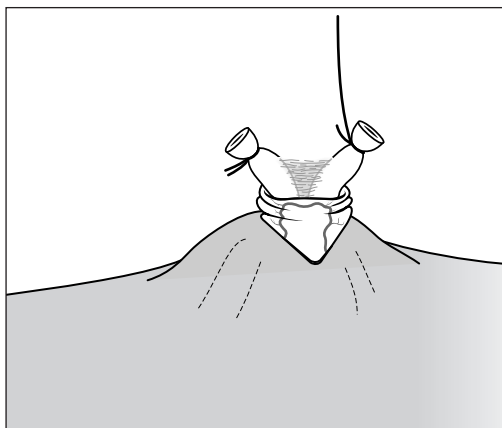
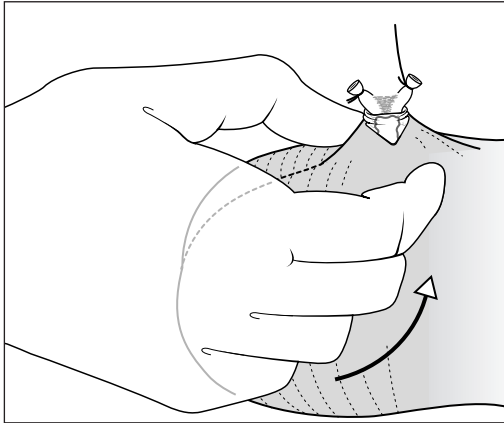
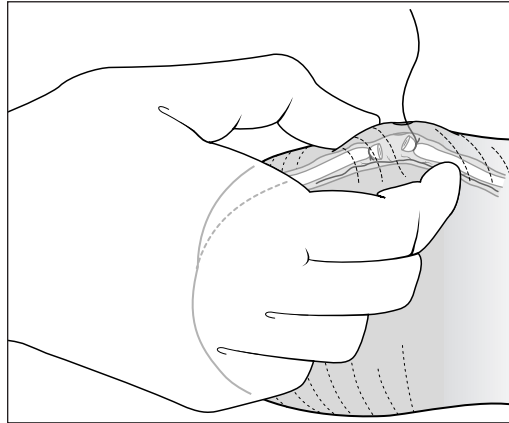


FIGURE 29. Steps in completing vasectomy by fascial interposition

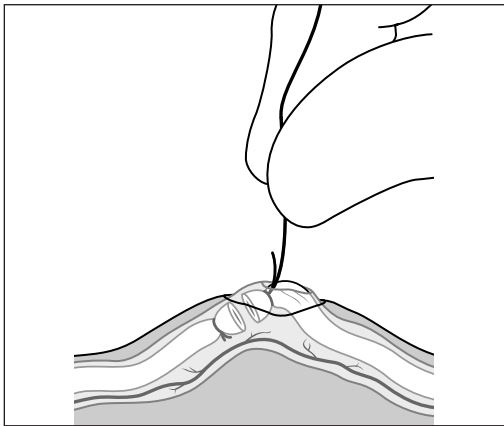
(a) The operator gently pinches and pulls up on the scrotum with the thumb and index finger



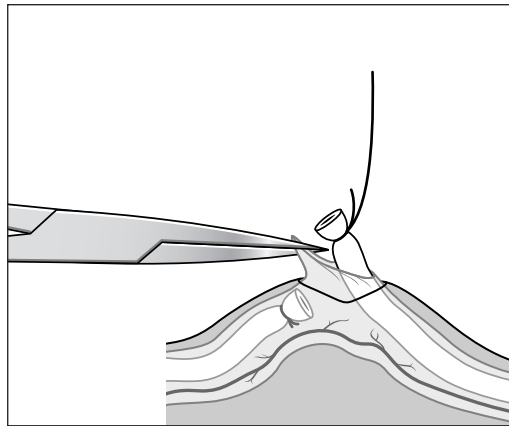
(b) The prostatic end of the vas passes between the fingers into the scrotum



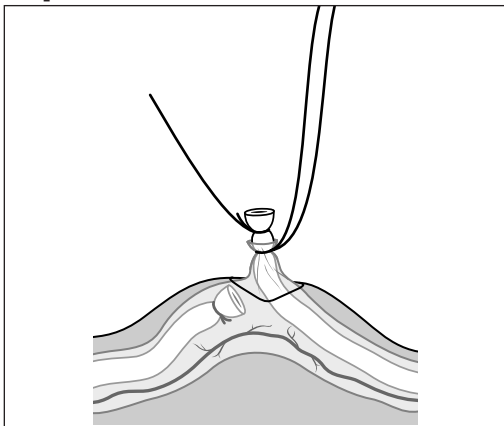
(c) The uncut ligature at the prostatic end is pulled through the puncture wound



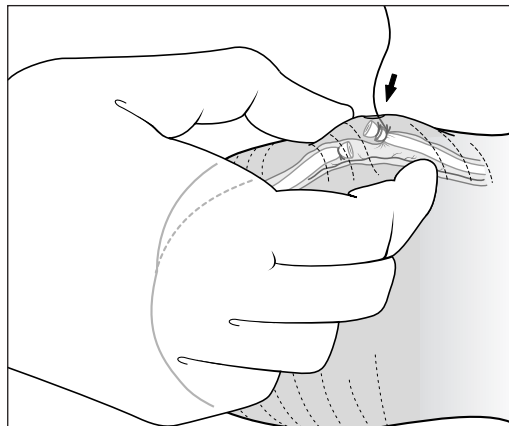
(d) With the tip of the dissecting forceps, the fascial sheath is grasped and held



(e) The fascial membrane is tied about 2 to 3 mm below the tie at the prostatic end



(f) The stump at the prostatic end is allowed to slip back into the scrotum



too close by pulling both ligatures. Separate both stumps by at least 1 cm (*Fig. 28e*). Inspect for bleeding and control it when it is present. **Before the ligature of the testicular end is trimmed, hemostasis must be assured.** After assuring that both stumps are separated, cut the ligature at the testicular end (*Fig. 28f*).

Allow both ends of the vas to drop back into the scrotum by gently pinching and pulling up on the scrotum with the thumb and index finger (*Fig. 29a*) until the prostatic end is felt passing through the fingers (*Fig. 29b*).

Start the fascial interposition technique by very gently pulling the uncut ligature of the prostatic end through the puncture wound (*Fig. 29c*). As the vas appears, it should be covered with the fascial sheath, which is seen as a translucent membrane covering the stump of the cut vas. If the translucent membrane (the fascial sheath) is not seen covering the vas, the vas should be dropped back into the scrotum and pulled out again, more gently.

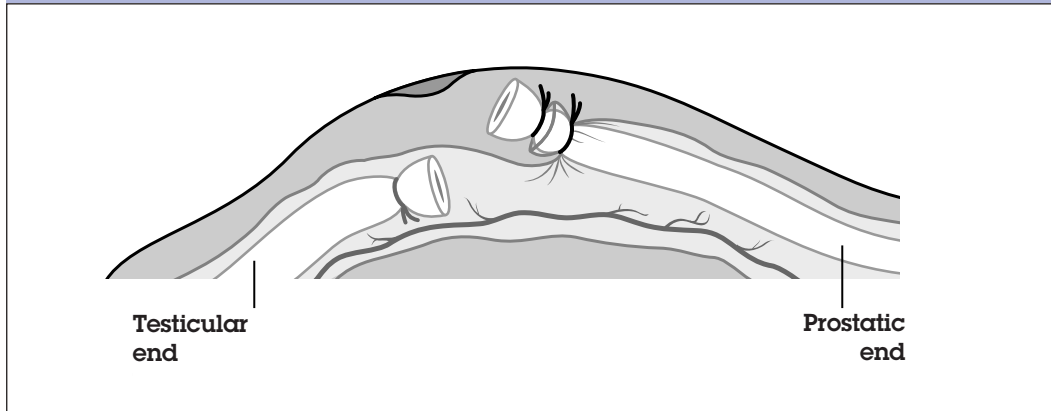Carefully grasp and hold tight the fascial membrane, using the tip of the dissecting forceps (*Fig. 29d*), tie the fascial membrane about 2 or 3 mm below the previous tie of the prostatic end (*Fig. 29e*), and cut both ends of the ligature. Allow the stump of the prostatic end to drop back into the scrotum by gently pinching the scrotum so that the stump falls back to its original position (*Fig. 29f*).

After assuring by palpation with the thumb and middle finger that the prostatic end is in the correct position, pull the single ligature just enough to see the stump of the prostatic end, then cut the single ligature and once again allow it to drop back into the scrotum. When fascial interposition is complete, the stump of the prostatic end should be outside the fascial sheath, and the stump of the testicular end should be inside the fascial sheath (*Fig. 30*).

PITFALL: Make sure not to tie the fascia with the vas while ligating to occlude the vas. If the fascia are tied with the vas during ligation, then fascial interposition will be difficult and may not be possible to perform.

Creating Fascial Interposition

FIGURE 30. The completed fascial interposition, with the stump of the prostatic end outside the fascial sheath and the stump of the testicular end inside the fascial sheath



Cautery. Another popular occlusion technique is cautery—electrosurgical (electrical coagulation) or thermal. This is done by inserting a needle electrode or cautery device into the vas lumen and desiccating the luminal mucosa of the vas to create a firm scar that will occlude the vas. With this method, only the inner layer of the vas (the mucosa) is sealed closed; the muscle wall of the vas remains intact.

There are many variations in the cautery technique, depending on the equipment used and the operator's preferences. For example, when a sharp-needle electrode is used, the operator pierces the vas wall with the needle and directs it into the lumen (*Fig. 31, page 48*). When a blunt cautery unit is used, however, the vas is first hemitransected, to permit the cautery tip to enter the lumen. If the vas is only partially transected at this stage, it cannot slip back into the scrotum (*Fig. 32, page 48*).

To achieve a graded desiccation of only the mucosal layer, the operator inserts 1.0 to 1.5 cm of the cold cautery tip into the lumen. Current is then applied, and the tip is slowly withdrawn. Depending on the equipment and the electrical current or strength of the battery, the time needed to cauterize the mucosal layer will vary. Doctors who are experienced with cautery usually note changes in the vas that indicate the mucosa has been desiccated. (For example, the mucosa blanches, and a small amount of smoke escapes from the tissue.) After cauterizing in one

FIGURE 31. Cautery with a sharp needle electrode (done in each direction)

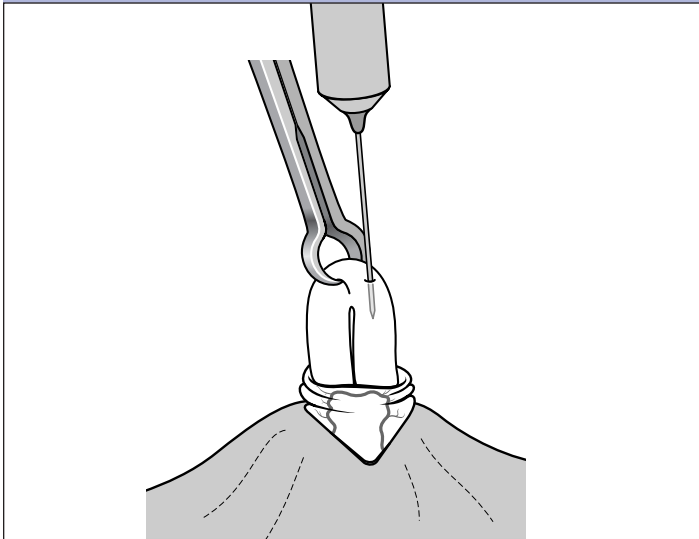


FIGURE 32. Cautery with a blunt wire inserted into the hemitranssected vas (done in each direction)

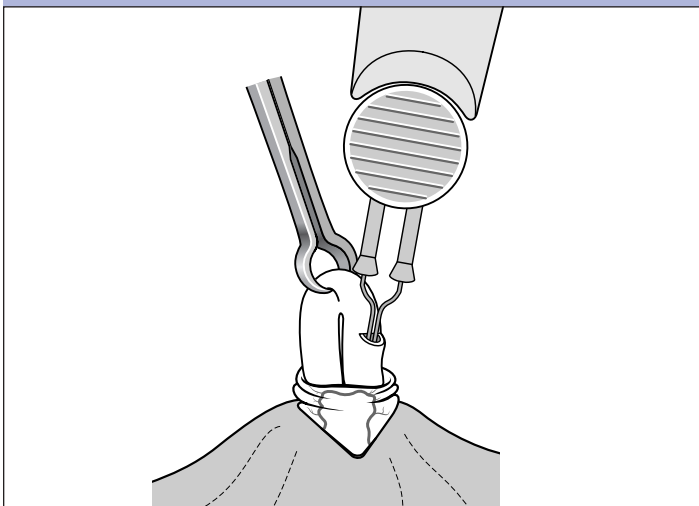
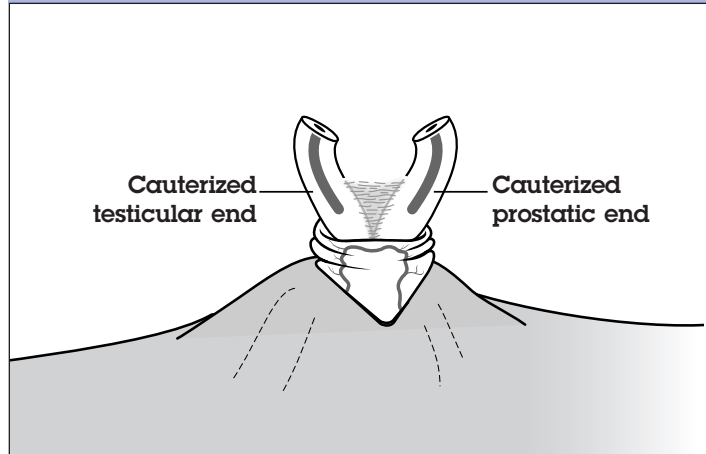


FIGURE 33. Sometimes a segment of the vas is removed following cauterization



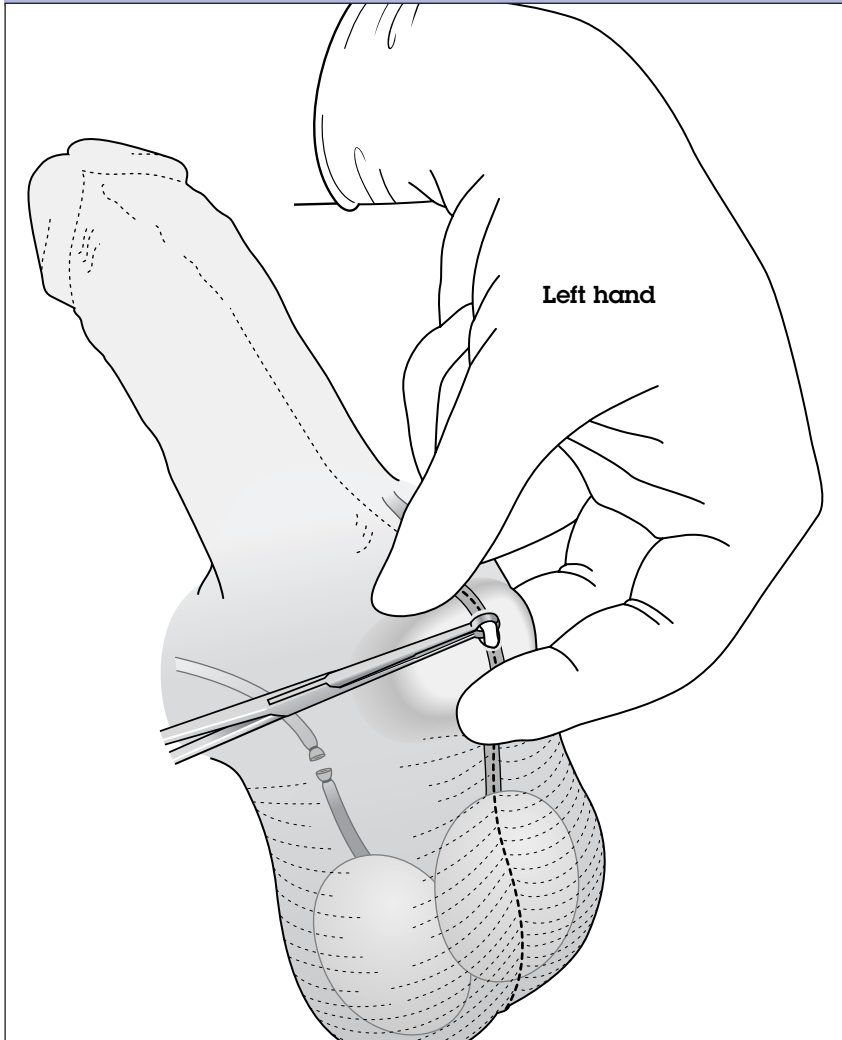
direction, the operator turns off the cautery unit to allow the tip to cool before cauterizing the vas in the other direction.

The vas is then divided. Some doctors remove a segment of the vas (*Fig. 33*) and others do not. Fascial interposition may also be used after the vas is occluded by cautery; however, there is no evidence that fascial interposition leads to a more rapid decrease in sperm counts than cautery alone.

The same procedure is followed for the second (that is, the left) vas.

PITFALL: When using cautery, avoid damaging the muscle of the vas; muscle damage can lead to necrosis, with subsequent sperm leakage, granuloma, and recanalization.

FIGURE 34. Isolating the left vas before occlusion



Adjust the left hand to grasp the left vas deferens, using the three-finger technique (*Fig. 34*). As described on page 21 of the anesthesia chapter, place the middle finger below the scrotum, with the thumb and index fingers above the scrotum; position the vas directly under the previously opened puncture site.

This position may be awkward at first, but with practice the right-handed operator will be able to isolate the left vas as smoothly as the right. Holding the vas with the left hand frees the right hand to handle the instruments (vice versa for the left-handed operator).

**Isolating
the Left Vas
before Occlusion**

**Applying
the Ringed
Clamp to the
Scrotal Skin
and Underlying
Left Vas**

Still using the three-finger technique, tightly stretch the skin overlying the vas so that it is as thin as possible. Open the ringed clamp, and press the tips onto the vas through the puncture site. Lock the clamp around the vas and overlying sheath (*Fig. 34*). As with the right vas, use the “palm-up” approach to ensure that the instrument is applied perpendicular to the vas (90 degrees) (*Fig. 11, page 25*).

Occasionally, the sheath and underlying vas cannot be fixed with the clamp because of local edema. Insertion of the clamp into the scrotal tissue may increase the risk of both trauma and infection. However, if the vas is directly under the puncture hole, inserting the clamp into the scrotal tissue probably will not contribute to trauma and infection. If the operator probes for the vas with the ringed clamp inside the scrotum, the risk of trauma and infection probably increases.

Grasping the left vas and sheath directly with the ringed clamp can make vasectomy easier to perform, particularly when the scrotal skin is thick.

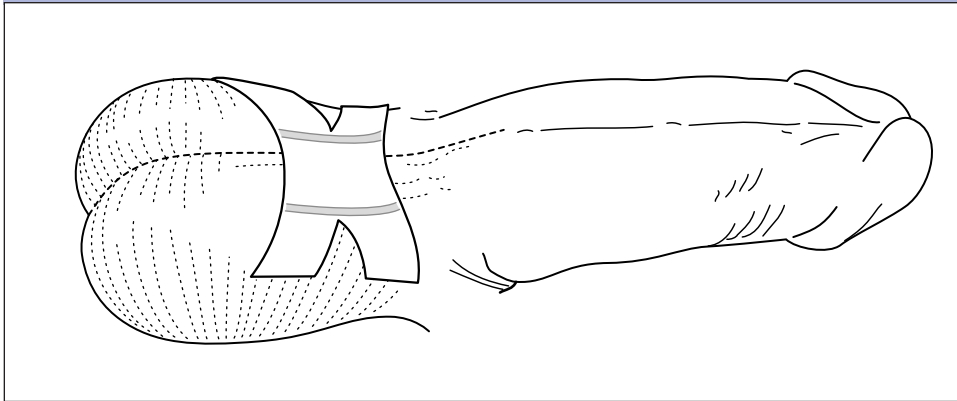
**Delivering, Elevating,
and Occluding
the Left Vas**

Follow the steps on pages 35 to 49 for delivering, elevating, and occluding the vas.

**Dressing
the Wound**

After both vasa have been occluded and returned to the scrotum, pinch the puncture site tightly for a minute, or ask the client to hold the gauze and apply pressure himself. Inspect for bleeding. If bleeding is present, hemostasis must be achieved. No skin sutures are necessary. Wash the small wound by swabbing with an antiseptic solution. A sterile gauze dressing can be held in place with a scrotal supporter or tape, or a Band-Aid can be used to cover the small wound. In *Figure 35 (page 52)*, note that the width of each end of the tape has been divided in half, allowing the tape to fit better on the round scrotum.

FIGURE 35. Dressing the wound



Men who have undergone vasectomy may leave the health facility after resting 30 minutes. If sedation has been used, monitor the client's vital signs every 15 minutes after surgery until they are stable.

Postoperative Care and Instructions

Explain to the client in simple language how to care for the wound, what side effects to expect, what to do if complications occur, where to go for emergency care, and when and where to return for a follow-up visit. Tell him that minor pain and bruising are to be expected and do not require medical attention. The man should seek medical attention if he has fever, if blood or pus oozes from the puncture site, or if he experiences excessive pain or swelling. Give the man a brief, simply written summary of the instructions.

It is essential that the client be informed of the low likelihood (but the possibility nonetheless) of vasectomy failure. He may resume normal activities and sexual intercourse with temporary contraception within two to three days, if he feels comfortable. The client or his partners will need to use another method of contraception during the first 12 weeks following vasectomy to avoid an unplanned pregnancy. Every client should be offered the opportunity to have a semen analysis. Ideally, one or two sperm-free semen specimens should be obtained from the client after vasectomy to be reasonably sure that the operation has been a success.

APPENDIX AND REFERENCES

Appendix

World Health Organization (WHO) Eligibility Criteria for Vasectomy Procedures*

Introduction

Considering the irreversibility or permanence of sterilization procedures, special care must be taken to assure a voluntary informed choice of the method by the client. Particular attention must also be given in the case of young people, men who have not yet been fathers, and clients with mental health problems, including depressive conditions. The national laws and existing norms for the delivery of sterilization procedures must be considered in the decision process.

There is no medical condition that would absolutely restrict a person's eligibility for sterilization. Some conditions and circumstances indicate that certain precautions should be taken.

The classification of the conditions into the different categories is based on an in-depth review of the epidemiological and clinical evidence relevant to medical eligibility. The programmatic implications of these updated medical criteria are still to be addressed, taking into account the various levels of service delivery. However, for the particular case of sterilization procedures, the following category definitions were developed.

Definitions

- A (Accept): There is no medical reason to deny sterilization to a person with this condition.
- C (Caution): The procedure is normally conducted in a routine setting, but with extra preparation and precautions.
- D (Delay): The procedure is delayed until the condition is evaluated and/or corrected. Alternative temporary methods of contraception should be provided.
- S (Special): The procedure should be undertaken in a setting with an experienced surgeon and staff, equipment needed to provide general anesthesia, and other back-up medical support. For these conditions, the capacity to decide on the most appropriate procedure and anesthesia regimen is also needed. Alternative temporary methods of contraception should be provided if referral is required or there is otherwise any delay.

*Adapted from: WHO, 2000.

Sterilization does not protect against sexually transmitted infections (STIs) or HIV. If there is risk of STIs/HIV, the correct and consistent use of condoms is recommended, either alone or with another contraceptive method. Male latex condoms are proven to protect against STIs/HIV.

Male Sterilization

Condition	Category	Rationale/Comments
Local infections		There is an increased risk of postoperative infection (Gohn & Bornside, 1989).
Scrotal skin infection	D	
Active STI	D	
Balanitis	D	
Epididymitis or orchitis	D	
Previous scrotal injury	C	
Systemic infection or gastroenteritis	D	There is an increased risk of postoperative infection (Gohn & Bornside, 1989).
Large varicocele	C	The vas may be difficult or impossible to locate; a single procedure to repair varicocele and perform a vasectomy decreases the risk of complications.
Large hydrocele	C	The vas may be difficult or impossible to locate; a single procedure decreases the risk of complications.
Filariasis; elephantiasis	D	The scrotum may be involved in severe elephantiasis, making it impossible to palpate the cord structure and testis.
Intrascrotal mass	D	This may indicate an underlying disease.

Male Sterilization (continued)

Condition	Category	Rationale/Comments
Cryptorchidism	C	If cryptorchidism is bilateral, and fertility has been demonstrated, this will require extensive surgery to locate the vas, and this becomes category S. If cryptorchidism is unilateral, and fertility has been demonstrated, vasectomy may be performed on the normal side and the spermogram checked, as per routine. If the man continues to have a persistent presence of sperm, more extensive surgery may be required to locate the other vas, and this becomes category S.
Inguinal hernia	S	Vasectomy can be performed concurrent with hernia repair.
Sickle cell disease	A	
Coagulation disorders	S	Bleeding disorders lead to an increased risk of postoperative hematoma formation, which in turn leads to an increased risk of infection.
Diabetes	C	Diabetics are more likely to get postoperative wound infections. If signs of infection appear, treatment with antibiotics needs to be given.
HIV/AIDS*		
High risk of HIV	A	No routine screening is needed. Appropriate infection prevention procedures, including universal precautions, must be carefully observed with all surgical procedures.
HIV-positive	A	
AIDS	S	If the man is currently suffering an AIDS-related illness, the procedure should be delayed.

* Barrier methods, especially condoms, are always recommended for prevention of STIs, including HIV.

References

- Alderman, P. M. 1991. Complications in a series of 1224 vasectomies. *Journal of Family Practice* 33(6):579-584.
- Arellano Lara, S., et al. 1997. No-scalpel vasectomy: Review of the first 1,000 cases in a family medicine unit. *Archives of Medical Research* 28(4):517-522.
- EngenderHealth. 2000. *Infection prevention: A reference booklet for health care providers*. New York.
- Gohn, I., and Bornside, G. H. 1989. Infections. In *Principles of surgery*, fifth edition, ed. by Schwartz, S. I., Shires, G. T., and Spencer, F. C. New York: McGraw-Hill, pp. 181-215.
- Huber, D. H. 1989. No-scalpel vasectomy: The transfer of a refined surgical technique from China to other countries. *Advances in Contraception* 5(4):217-218.
- Kendrick, J. S., et al. 1987. Complications of vasectomies in the United States. *Journal of Family Practice* 25(3):245-248.
- Kumar, V., et al. 1999. An evaluation of the no-scalpel vasectomy technique. *BJU International* 83(3): 283-284.
- Li, S. Q., et al. 1991. The no-scalpel vasectomy. *Journal of Urology* 145(2):341-344.
- Medical Economics. 2002. *Physicians' Desk Reference*, 56th edition. Montvale, NJ.
- Nirapathpongporn, A., Huber, D. H., and Krieger, J. N. 1990. No-scalpel vasectomy at the King's Birthday vasectomy festival. *Lancet* 335(8694):894-895.
- Philp, T., Guillebaud, J., and Budd, D. 1984. Complications of vasectomy: Review of 16,000 patients. *British Journal of Urology* 56(6):745-748.

- Pollack, A. P., and Barone, M. A. 2000. Male sterilization. In *Gynecology and obstetrics, Vol. 6: Fertility regulation, psychosomatic problems, and human sexuality*, revised edition 2000, ed. by J. Sciarra. Philadelphia: Lippincott Williams & Wilkins, Chap. 47.
- Skriver, M., Skovsgaard, F., and Miskowiak, J. 1997. Conventional or Li vasectomy: A questionnaire study. *British Journal of Urology* 79(4):596-598.
- Sokal, D. C., et al. 1999. A comparative study of the no scalpel and standard incision approaches to vasectomy in 5 countries. The Male Sterilization Investigator Team. *Journal of Urology* 162(5):1621-1625.
- Sokal, D., et al. 2001. Vasectomy with fascial interposition vs. ligation and excision alone: A randomized controlled trial. Presentation at the annual meeting of the Association of Reproductive Health Professionals. December 12-15, Washington, DC.
- Viladoms Fuster, J. M., and Shihua Li, P. 1994. Vasectomía sin bisturío. *Archivos Espanoles de Urologia* 47(7): 695-701.
- World Health Organization (WHO). 1988. *Technical and managerial guidelines for vasectomy services*. Geneva.
- WHO. 2000. *Improving access to quality care in family planning: Medical eligibility criteria for contraceptive use*, second edition. Geneva.